

**JSUM Ultrasound Elastography Practice Guidelines
Breast**

Kazutaka Nakashima¹

Tsuyoshi Shiina²

Masaru Sakurai³

Katsutoshi Enokido⁴

Tokiko Endo⁵

Hiroko Tsunoda⁶

Etsuo Takada⁷

Takeshi Umemoto⁸

Ei Ueno⁸

- 1) Department of General Surgery, Kawasaki Medical School, Okayama, Japan
- 2) Department of Human Health Sciences, Graduate School of Medicine, Kyoto University, Kyoto, Japan
- 3) Department of Ultrasonography Center, St. Marianna University School of Medicine, Kanagawa, Japan
- 4) Department of Breast Surgical Oncology, Showa University School of Medicine, Tokyo, Japan
- 5) Department of Advanced Diagnosis, National Hospital Organization Nagoya Medical Center, Aichi, Japan
- 6) Department of Radiology, St. Luke's International Hospital, Tokyo, Japan
- 7) Center of Medical Ultrasonics, Dokkyo Medical University, Tochigi, Japan
- 8) Department of Senology, Tsukuba Medical Center Foundation, Ibaraki, Japan

Abstract

Ten years have passed since the first elastography application “Real-time Tissue Elastography™”. Now there are several elastography applications in existence. The Quality Control Research Team of The Japan Association of Breast and Thyroid Sonology (JABTS) and the Breast Elasticity Imaging Terminology and Diagnostic Criteria Subcommittee, Terminology and Diagnostic Criteria Committee of the Japan Society of Ultrasonics in Medicine (JSUM) have advocated Breast Elastography Classifications for exact knowledge and good clinical use. We suggest two types of classifications, the technical classification and the classification for interpretation. The technical classification is made to use vibration energy and to make images, and also shows the way to get a good elastic image. The classification for interpretation is prepared on the basis of the interpretation of evidence in this decade. And we at the end described about the character and the specificity of each vender equipment. We expect the present guidelines will be useful for many physicians and examiners throughout the world.

Keywords : Elastography, Breast, Strain elastography, Shear wave elastography, Ultrasound

Footnote : The breast section of this guideline is written based on the draft report³⁾ provided by Elastography Subteam, Quality Control Research Team, JABTS(The Japan Association of Breast and Thyroid Sonology).

1. Introduction

Tissue elasticity imaging (elastography, strain imaging) is the most noteworthy of the new technologies found in the recent diagnostic ultrasound systems. First, we will briefly explain the concept and history of this technology.

Cancer tissue becomes harder as the density of the blood vessels and cells increases, and it is said that this hardening process begins in the early stage of cancer. The idea of using this stiffness information for diagnosis evolved into a new diagnostic imaging method for detecting tissue elasticity (stiffness) and evaluating it noninvasively and objectively using ultrasound. Ueno et al. reported a dynamic test¹⁾ for the evaluation of stiffness by applying real-time ultrasonography in 1987. This test consisted of manually compressing the breast and visually assessing tissue stiffness.

The concept of attempting evaluation by imaging stiffness itself was published by Ophir et al. from The University of Texas in 1991 under the name of elastography²⁾. The concept of elastography involves imaging the displacement of tissue that has been compressed by pressing the probe against the skin, i.e., strain distribution, and evaluating the stiffness of the site of involvement as diagnostic information. The combined autocorrelation method, which detects tissue displacement more rapidly and accurately, was announced in 1996, but the computing power of the system was not sufficient to provide real-time images using the signal processing technology available at that time. A tissue elasticity imaging method was announced by Shiina (Tsukuba University, currently Kyoto University) et al. in 2001. An ultrasound elastography system suitable for actual clinical use was subsequently released in 2003 under the name of Real-time Tissue Elastography™ (RTE). The system, which could be used with confidence as part of routine examinations thanks to an improved algorithm and use of a unit with adequate computing power, ushered in the widespread use of ultrasound "elastography" throughout the world. Elastography technology has since improved together with advances in diagnostic ultrasound systems. Current elastography systems can not only differentiate between benign and malignant tissue but also evaluate histological information by depicting the distribution of tissue stiffness and evaluate the therapeutic effect of treatment with anti-cancer agents. They are becoming a tool that allows diagnosis and evaluation of not only masses but also non-masses.

Thus, it has been 10 years since the first system with elastography capability became available on the Japanese market. At first, Hitachi (currently Hitachi Aloka Medical) was the only company selling an elastography system, but systems with elastography capability are currently available from GE Healthcare, Siemens, Philips Healthcare, Supersonic Imagine, Toshiba Medical, Zonare, and Samsung Medison (Fig.1).

More recently, systems equipped with methods that apply strain have become available. They include not only systems with strain elastography, which involves manual compression vibration, but also systems equipped with acoustic radiation force impulse (ARFI) and shear wave elastography technology that supplies vibration energy by means of irradiation with the radiation force. These methods share the concept of bringing qualitative diagnostic capability, i.e., imaging and numerical expression of the stiffness of a target, into the field of ultrasonography, which is primarily concerned with morphological diagnosis, but they differ in terms of their theory, the direction of their development, and their accuracy. Moreover, there are various methods and terms related to diagnostic assessment such as elasticity score (Tsukuba score, strain pattern), strain ratio (fat-lesion ratio (FLR)), E/B ratio (width ratio, length ratio), kPa, and Vs, which often leads to confusion when trying to first become accustomed to elastography.

The Quality Control Research Team of the Japan Association of Breast and Thyroid Sonology (JABTS) and

the Breast Elasticity Imaging Terminology and Diagnostic Criteria Subcommittee, Terminology and Diagnostic Criteria Committee of the Japan Society of Ultrasonics in Medicine (JSUM) have advocated an Elastography Classification table and reported it in the Journal of Breast and Thyroid Sonology³⁾ to help organize and understand this wide variety of elastography. This report will describe this classification and present and explain the evidence for elastography, its clinical utility, the characteristics of each method, and clinical images, etc..

2. Classification

2-1 Classification by Technical Method

The Accuracy Control Research Team of JABTS and the Breast Elasticity Imaging Terminology and Diagnostic Criteria Subcommittee, Terminology and Diagnostic Criteria Committee of JSUM advocated the following classification (Table 1) in 2013.

In this table, vibration energy is classified (columns) into Manual Compression (that was achieved by vibration caused by manual compression or involuntary movement of arm muscles, etc., or vibration caused by patient muscular contraction or breathing, etc.) and Acoustic Compression (that was achieved by the ultrasound irradiation force from a probe), and imaging information is classified (rows) as strain imaging, which is calculated based on strain, and shear wave imaging, which is calculated based on the propagation speed of shear waves. In the actual clinical practice, shear wave imaging with manual compression for applying vibration/compression is not used for breast imaging, so it should be classified into the following three groups.

1. Strain Elastography : Hitachi Aloka, GE Healthcare, Philips Healthcare, Siemens, Toshiba
2. Acoustic Radiation Force Impulse (ARFI) Imaging : Siemens
3. Shear Wave Elastography : SuperSonic Imagine, Siemens

2-2 Classification by Interpretation

At present, the three main diagnostic methods are as follows when classifying them based on the reported evidence and similar findings from clinical investigations and based on the manufacturer's recommended method in the absence of such reports. Each method has its advantages and disadvantages, and evidence has been reported for some and not for others. A detailed explanation of each unit will be given in the latter half of this report.

1. Methods where color pattern diagnosis is performed based on color images from elastography, and a diagnosis is made based on the assessed score

Elasticity score (Tsukuba score, strain pattern):

Hitachi Aloka Medical, GE Healthcare, Philips Healthcare, Siemens, Toshiba Medical

Tozaki's Score

SuperSonic Imagine

2. Methods where gray-scale images from elastography are compared with B-mode images, and a diagnosis is made based on the size ratio of the target lesion

EI/B ratio(E/B ratio), width ratio, length ratio:

Philips Healthcare, Siemens, GE Healthcare

3. Methods where a diagnosis is made by assigning a numerical value to the stiffness (tissue elasticity)

Strain ratio (fat-lesion ratio (FLR)) (how many times harder is it than subcutaneous fat):

Hitachi Aloka Medical, GE Healthcare, Philips Healthcare, Toshiba Medical, Siemens

kPa (unit of stiffness), m/s (unit of sound velocity): SuperSonic Imagine, Siemens

3. Current Clinical Utilities

At present, the following five clinical utilities hold promise.

1. By adding elastography to the scanning of masses that require a closer examination according to US-BIRADS or the JABTS Screening Group's Recall Criteria⁴⁾, some could be lowered to Category 2, which has been demonstrated by prospective clinical studies. Consequently, specificity may be improved by including elastography in the breast ultrasound scanning. It is hoped that this will decrease the frequency of intervention such as unnecessary biopsy, reduce the burden placed on patients, and lower public healthcare costs.
2. By adding elastography to the scanning of masses that require closer examination according to US-BIRADS or the JABTS Screening Group's Recall Criteria, it has been reported that there are Category 3 lesions that are raised to Category 4. Consequently, it is hoped that the diagnostic confidence of malignancy will be improved by including elastography in the breast ultrasound scanning.
3. Whether elastography should be included in screening remains to be seen, but it is hoped that including elastography in screening will lower the recall rate and improve the positive predictive value of screening.
4. At the present time, preoperative chemotherapy, preoperative hormone therapy, preoperative molecular-targeted drug therapy, and other therapies are actively used in a clinical setting in the case of breast cancer, but the application of elastography in the assessment of preoperative chemotherapy has already been reported¹³⁾. Therefore, it is hoped that elastography will be useful for the therapeutic evaluation of chemotherapy and other therapies.
5. Breast-conserving surgery is the mainstay of breast cancer surgery, but breast cancer often has an intraductal component, making an assessment of the extent of resection important. The utility of elastography for determining the extent of resection has been reported¹¹⁾. The intraductal component does not take the form of a mass. Rather, it often takes the form of a non-mass abnormality⁴⁾ advocated by the Japan Association of Breast and Thyroid Sonology. Given that elastography is useful for depicting of this intraductal component, it is hoped that it becomes useful in the differential diagnosis of non-mass abnormalities.

4. Important Points of Elastography

The following three points are important with respect to the clinical use of and a diagnosis with elastography.

1. Understand the differences in information yielded by different methods: The method for measuring strain and the imaging method differ from manufacturer to manufacturer. For example, "spatial correlation method," "phase difference detection method," and "combined method" are used. Each method has its advantages and disadvantages, and there are slight differences in their accuracy. Therefore, it is important to thoroughly understand the characteristics of each method and the unit being used in order to make a correct diagnosis.
2. Displayed ROI: It is generally recommended that the area from the subcutaneous layer to the pectoralis major muscle (excluding ribs and lungs) be included in the displayed ROI. Since many Strain elastography systems express the findings as relative values, it is important to choose a wide displayed ROI where the lesion accounts for no more than one-fourth of the displayed ROI in order to include plenty of normal soft tissue in the displayed ROI. However, there is no need to worry about this in the case of eSie Touch Elasticity Imaging as it is not dependent on the displayed ROI setting.
3. Use the appropriate imaging according to the unit used and the location of the target lesion: The method for supplying vibration energy differs depending on the elastography method. In this report, handling of the probe to achieve good elastography images is classified into three categories: "no manual compression," "minimal vibration," and "significant compression." In addition, there are important factors associated with obtaining good images such as the angle of the probe to the skin and breast structure and the degree of compression. A concrete description of them is provided next.

5. Practical Advice

Be mindful of the following five points when taking images.

5-1 Get a good B-mode image to get a good elastography image

Elastography images are often generated based on the raw data from B-mode images, and many methods require good B-mode images for diagnosis. Therefore, it is important to get quality B-mode images first. For elastography imaging, it is recommended that the examiner always switch to elastography mode after first ascertaining that the circumstances are ideal for getting quality B-mode images (Fig.2).

5-2 Keep the angle of the probe perpendicular to the skin!.

Both manual compression and acoustic radiation force are meaningless if the probe moves from directly above the target. Moreover, the target being observed will move with even a slight change in the probe angle. Therefore, it is important to ensure that you find a position that allows for stable vibration, compression, and motionlessness. Specifically, the lesion's location and the angle of the probe are important, and it is of paramount importance to ensure that the probe is perpendicular to the skin (Fig. 3).

5-3 Probe orientation in the radial scan line should be similar to the breast duct!

Placing the probe parallel to the course of the breast ducts, i.e., radial to the breast, makes it easier to get a stable image with little breast movement during vibration/compression. In the peripheral region of the breast, however, an orthogonal cross section relative to the radial direction makes imaging easier with little tissue movement.

In general, it is important to place the probe perpendicularly to the skin and also perpendicularly to the breast, and attention should be paid to making sure breast tissue does not move (Fig. 4).

5-4 In the case of Strain elastography, know the best maneuver for each system and target!

There are three main types of compression/vibration methods: "no manual compression," "minimal vibration," and "significant compression," and they are explained below. It is generally not necessary to generate much vibration when imaging shallow lesions, but greater vibration tends to be necessary when imaging deep lesions. The most useful imaging method should be used according to the unit used and the location of the target lesion.

5-4-1 No manual compression

Place the probe vertically on the skin without consciously applying any vibration/compression. Keep the probe lightly touching the skin and try not to apply pressure. This method gets vibration energy from vibration caused by involuntary muscle contraction in the hand and vibration caused by muscle contraction and breathing of the patient. The image does not move at all, so extremely fine image display is possible. However, adequate elastography images cannot always be obtained in the case of deep lesions due to the low level of vibration energy.

This maneuver is recommended for the equipment of Semense' and Philips' Supersonics' equipment.

(Figs. 5 & 6).

5-4-2 Minimal vibration

Place the probe vertically on the skin and apply very mild vibration. Make sure that you do not push too hard. The vibration stroke should be no more than 1 mm. Keep the probe lightly touching the skin, and apply extremely fine vibration with a fast cycle, as if lifting up the skin with the probe, likening the jelly to glue. Vibration should be applied as if you are not moving your hand at all when you look at it. This method can be used for relatively shallow lesions to moderately deep lesions, and it allows elastography imaging of fine targets several millimeters in size such as non-mass abnormalities. It is also possible to

depict in detail the distribution of soft areas (areas with significant strain), and it provides a great deal of diagnostic information. Systems available from Hitachi Aloka, GE Healthcare, and Philips Healthcare support this method (Figs. 7 & 8).

5-4-3 Significant compression

Place the probe vertically on the skin, and apply fairly firm compression (about 1-3 mm). This method has been recommended since the beginning of the development of many elastography applications. It is similar to the dynamic test in B-mode imaging, and it serves as a basic elastography imaging method. As long as the tumor is fairly large, adequate elastography images of lesions at most depths can be expected. Even when "minimal vibration" is recommended for an application, it is often possible to get an adequate elastography image using this method when imaging lesions that are quite deep.

It is recommended for Toshiba, GE Healthcare, and Hitachi Aloka systems (Figs. 9 & 10).

5-5 Examination method for Shear Wave Elastography

Since vibration energy is directly emitted from the probe, keep the probe vertical to the skin, lightly touching it, without pressing strongly, and be careful not to move it. No vibration/compression needs to be applied by the examiner. It can be thought of as being almost the same as no manual compression in the case of strain elastography. This method is recommended for systems available from Siemens and SuperSonic Imagine (Figs. 11 & 12).

6. System Characteristics, Diagnostic Approaches, Evidence, and Clinical Images in Each Group

System manufacturers are divided into three groups by elastography method, and the characteristics of manufacturers are explained by group.

1. Strain elastography : Hitachi Aloka、GE Healthcare、Philips Healthcare、Siemens、Toshiba
2. Acoustic Radiation Force Impulse (ARFI) Imaging : Siemens
3. Shear wave elastography : SuperSonic Imagine、Siemens

6-1-a Strain Elastography : Hitachi Aloka Medical

A Diagnostic approach and evidence

Since real-time tissue elastography (RTE) is the first elastography to be used clinically, it is the most common elastography in Japan, where elastography is equated with RTE. Naturally, it has been researched extensively. Not only can it be used to differentiate benign and malignant tumors but it has also been reported to be effective for therapeutic evaluation and for lesions that do not take the form of a mass.

Diagnosis is generally performed using elastography color images. It is used clinically for not only masses but also for non-mass abnormalities.

a-1 Utility for differentiating benign and malignant masses

Elasticity score (Tsukuba score) and strain ratio (FLR) are widely used. Recently, they are being used for purposes other than differentiating benign and malignant masses.

a-1-1 Tsukuba score (Elasticity score)

What sparked the widespread clinical use of RTE was the introduction of the elasticity score (Tsukuba Score)⁵⁾ advocated by Itoh et al. It is a five-point scale that compares the hypoechoic area of a mass with areas of decreased strain using RTE. Its sensitivity, specificity, and accuracy for differentiating between benign and malignant breast masses were reported to be 86.5%, 89.9%, and 88.3%, respectively (Fig. 13 excerpted from the article by Itoh et al.).

A diagnostic approach where color pattern diagnosis is performed based on color images is the most common form of elastography in Japan. In this diagnostic approach, a score from 1 to 5 is assigned, as shown in the figure, based on the color (balance of green and blue) inside the target tumor and the surrounding area on elastography, with a higher score indicating a higher diagnostic confidence of malignancy.

Since the report by Itoh et al., use of RTE has become widespread. Several clinical studies have been reported, and it is now the most standard diagnostic approach. Raza S et al.⁶⁾ conducted a prospective clinical study using Itoh et al.'s elasticity score, and they reported a sensitivity of 92.7% and a specificity of 85.8%. As a result, it is our understanding that many clinical investigators recognize elastography as being useful.

What should be noted when making a diagnosis using this method is the importance of choosing an ROI that includes plenty of normal soft tissue where the lesion accounts for no more than one-fourth of the ROI during imaging. It is a simple and easy-to-understand method, but if we had to list some shortcomings, they would include the fact that judgments tend to be subjective, or that it cannot be used for massive tumors or large, irregular tumors since assessment is affected by the area ratio of the tumor and the surrounding area.

a-1-2 Strain ratio (FLR: fat-to-lesion strain ratio)

This diagnostic approach was advocated by Ueno et al.⁷⁾ for the purpose of quantitatively evaluating

stiffness since the diagnosis by means of the color pattern can be subjective. As shown in the figure, it is the ratio of the strain in a mass to the strain in subcutaneous fat, and it can be thought of as a semi quantitative method for numerically evaluating how many times stiffer a target mass is as compared with subcutaneous fat (Fig. 14).

The target ROI for the tumor should not protrude from the interior of the tumor in B-mode. The target ROI for subcutaneous fat should be a circle of sufficient size, and limited to the skin and fat that does not contain breast tissue.

Since it is possible to evaluate the stiffness of one specific part of a mass by setting the target ROI, not only is it possible to measure massive tumors, it is also possible to evaluate the stiffness of non-mass abnormalities. The stiffness of a tumor is an approximation, but quantitative evaluation is possible. As such, it is easy to apply, and the results of clinical studies using this diagnostic approach have already been reported.

Farrokh et al.⁸⁾ reported sensitivity of 94.4% and specificity of 87.3% with a cut-off above 2.9 in a prospective study using strain ratio (FLR).

Alhabshi SM et al.⁹⁾ reported that width ratio and strain ratio were the most useful, with a cut-off value of 1.1 for width ratio and a cut-off value of 5.6 for strain ratio, in a study using B-mode, strain pattern (elasticity score), width ratio, and strain ratio, and they stated that a semi quantitative diagnostic approach was useful for RTE.

a-1-3 Accuracy control

Chang JM et al.¹⁰⁾ analyzed factors that affect the accuracy of elasticity scores in a prospective study, and they reported their findings on accuracy control of RTE elastography. They reported that the breast being thin at the location of the lesion (the target lesion being located in a shallow area) was the biggest factor affecting elastography image quality, and they mentioned that the accuracy of elastography differed depending on the depth of the lesion and that accuracy control was necessary.

a-2 Estimation of pathological features (diagnosis of non-mass abnormalities and differentiation of pathological features)

Many clinicians think RTE reflects pathological features relatively well, and there have been many reports of comparisons with resected specimens. A minimal breast cancer elastography image, a macroscopic image of the resected specimen, and an image of hematoxylin and eosin staining are shown in Fig.15a and 15b, 15c. The hard part (blue) on elastography corresponds to the spread of breast cancer in the radial direction.

In addition, RTE subtly depicts not only hard regions (areas with little strain) but also soft regions (areas with much strain), greatly increasing the diagnostic range of ultrasound. Much RTE research today focuses on the estimation of pathological features, even more so than differentiating the no malignancy and malignancy of masses.

Breast-conserving surgery is the mainstay of breast cancer surgery, but breast cancer often has a widespread intraductal component, making assessment of the extent of resected area important. The utility of elastography for determining the extent of resection has been reported by Nakashima et al.¹¹⁾, who used elastography for the presumptive diagnosis of tumor spread before breast-conserving surgery, reported that elastography could be expected to be effective for evaluation of the intraductal component (Fig. 16a,b & 17 excerpted from article by Nakashima et al.). The intraductal component, which does not take the form of a mass, is similar to a non-mass abnormality. As elastography was useful for assessing the intraductal

component, which is similar to a non-mass abnormality, it is hoped that elastography will also be used for non-mass abnormalities in the future.

Adamietz BR et al.¹²⁾ reported that elastography color patterns were useful for comparing and differentiating phyllodes tumors and fibroadenomas.

a-3 Utility in evaluation of the effectiveness of drug therapy

RTE has a long history and is a very complete technology, and a variety of research is being conducted in areas other than its application in the diagnosis of masses. Hayashi et al.¹³⁾ evaluated the therapeutic effect of preoperative chemotherapy using FLR and reported its utility for that purpose. At the present time, preoperative chemotherapy, preoperative hormone therapy, preoperative molecular-targeted drug therapy, and other therapies are actively used in a clinical setting in the case of breast cancer, and it is hoped that elastography will be used in the assessment of response to such preoperative therapies in the future.

a-4 Utility in diagnosis of axillary lymph node metastasis

Wojcinski et al.¹⁴⁾ retrospectively analyzed the presumptive diagnosis of axillary lymph node metastasis in 165 breast cancer patients without metastasis and without lymph node involvement and 15 breast cancer patients with metastasis. They reported that the sensitivity of palpation, B-mode imaging, Doppler imaging, and RTE was 13.3%, 40.0%, 14.3%, and 60.0%, respectively, and the specificity was 88.4%, 96.8%, 95.6%, and 79.6%, respectively. Thus, RTE was predominantly more sensitive.

a-5 3D Elastography

As mentioned above, RTE can acquire stable and dense elastography images using minute vibrations. Therefore, 3D strain images can now be constructed. Products containing this technology, which has been branded "4D elastography," have been available since 2011. It is hoped that it will be effective in terms of depicting the direction and spread of lesions using MPR images and 3D images. The pathological features of the same lesion are displayed on both 4D elastography images and 3D reconstructed images. One can see that the tumor shape and the spread and direction are depicted in 3D (Fig. 18 & 19).

B Recommended imaging techniques

RTE supports "minimal vibration," and "significant compression." It is certainly possible to make a diagnosis of many masses using the "significant compression" approach to elastography, but it is impossible to acquire elastography images in the case of minute lesions only millimeters in size such as intraductal lesions using this approach. Therefore, "minimal vibration" is recommended for elastography imaging of minute lesions. In the case of deep lesions, however, "significant compression" may be better for acquiring adequate elastography images as other approaches might not provide sufficient vibration energy.

For beginners, it may be useful to refer to a strain graph that shows in real time the changes in strain over time in order to assist the above techniques, but this does not apply to experts as imaging accuracy can be assessed using the image for the most part.

C Displayed ROI

A characteristic of RTE is that strain within the displayed ROI is expressed as green for average stiffness, blue for hard areas, and red for soft areas. Therefore, the displayed ROI should partly include the area from subcutaneous tissue to the pectoralis major muscle, and the horizontal direction should be expanded to the utmost limit, in order to more accurately express relative values. The ribs and lungs should not be included. All of the strain data within the B-mode image range are acquired in the case of new systems equipped with RTE, so it is possible to change the position and size of the displayed ROI even after freezing the image.

D Imaging time

In the case of RTE, the color is visualized immediately after the initial vibration (about 1 sec), but imaging needs to continue until the color of the entire target is completely stable in order to acquire reliable measurement results. The amount of time required will decrease as your skill improves, so it is recommended that you take plenty of time and continue until the color is stable at first.

E Images and pathological features

The most useful point to remember in usual clinical practice is that information that can be used to determine no malignancy without cytology or biopsy can be acquired by differentiating cysts, fibroadenomas, and fat islands (adipose tissue in the mammary gland) based on mass images in patients recalled for closer examination. It is also a source of information for further confirming that a malignant tumor is a hard tumor. Images that illustrate this important point are provided. Representative images that illustrate the usefulness of elastography for diagnosis are provided (Fig. 20-30).

E-1 Cysts

In the case of elastography, it is possible to judge whether the inside of a mass is liquid in nature if the inside is visualized as soft.

In the case of RTE, an area like a red band in the deep part of a mass that is nearly anechoic is visualized. This is a unique pattern that appears due to the absence of reflection intensity in the mass and increased strain directly under it, and it is thought to indicate that the inside of the mass is liquid in nature. It presents as blue, green, and red layers beginning in the shallow area, which is referred to as the BGR sign.

E-2 Fibroadenoma

Fibroadenomas are classified into two main pathological types, i.e., those with a pericanalicular pattern and those with an intracanalicular pattern¹⁵⁾. They are benign tumors that are frequently encountered in an usual clinical practice. Fibroadenomas often contain changes that look like normal mammary gland tissue, and some researchers classify them into those with an organoid pattern or a complex pattern depending on the proliferative component or the structure, which makes the differential diagnosis complicated during diagnostic imaging. Therefore, it produces several morphologies on B-mode images and elastography color patterns. In some fibroadenomas with an intracanalicular pattern or pericanalicular pattern, the interior of the tumor is visualized as comparable to the surrounding mammary gland or as mildly hard on elastography, and a membrane that slides softly is observed as a red band at the tumor margin. In such cases, a fibroadenoma should be strongly suspected. However, fibroadenomas that present other elastography images are often displayed as being almost as hard as a malignant tumor. Therefore, differentiation is difficult using only ultrasound imaging, even if elastography is included, and biopsy is recommended.

E-3 Fat island(Isolated fat tissue in atrophic breast gland)

It is easy to distinguish fat in mammary tissue with elastography. This is because fat is displayed as a green area with thin red bands expanding sideways in mammary tissue due to its composition.

E-4 Malignant tumors

Many malignant tumors are visualized as clearly harder than benign lesions and normal tissue, so elastography improves the diagnostic confidence.

It is easy to confuse mucinous carcinoma with fat at first glance, and it is difficult to identify on B-mode images, but the outline and homogeneous stiffness of the tumor is distinct on elastography. Invasive ductal breast cancer (WHO: Invasive carcinoma, Nonspecific type) and invasive lobular carcinoma are

visualized as quite clearly blue, but ductal carcinoma in situ (DCIS) and other noninvasive carcinomas are depicted as slightly blue, or often as blue in a disjointed manner; however, it improves the diagnostic confidence of the clear presence of a hard lesion.

F Outstanding issues

Accuracy differs between shallow sites and deep sites due to problems associated with the propagation of vibration energy. Further improvement of applications and adjustments to imaging methods are needed.

At present, reports related to strain ratio have used different cut-off values, so we feel the need for a multicenter study that includes accuracy control. A multicenter prospective study with accuracy control to determine the cut-off value that should ultimately be recommended is needed.

G Summary

At the present time, the utility of RTE for differentiating of the no malignancy and malignancy of masses and differentiation of non-mass abnormalities is almost certain, and elasticity score (Tsukuba score) and strain ratio (FLR) are standard diagnostic approaches.

As mentioned above, RTE can subtly depict not only hard regions (areas with little strain) but also soft regions (areas with much strain). As a result, elastography research is moving toward estimation of more detailed pathological features of non-mass abnormalities and masses, not just differential diagnosis of the no malignancy and malignancy of masses. The latest RTE systems provide resolution that allows visualization of both areas with much strain and those with little strain with millimeter precision. As such, its use is expected to become even more widespread in the future.

6-1-b Strain Elastography : Philips Healthcare

A Diagnostic approach and evidence

This method is similar to RTE. It is recommended that the diagnosis be made with the elasticity score (Tsukuba score) and the strain ratio (FLR) using elastography color images, but gray-scale image display is also available, and the diagnosis can also be made based on the E/B ratio by means of comparison with B-mode images (Fig. 31 & 32).

Using a Philips Healthcare iU22 system, Stachs et al.¹⁶⁾ demonstrated its utility in 224 breast masses in 215 subjects using the Tsukuba score. They simultaneously evaluated tumors using the strain ratio and reported that the strain ratio was predominantly higher in malignant tumors, i.e., 3.04 ± 0.9 (Mean \pm SD) for malignant tumors versus 1.91 ± 0.75 for benign tumors.

Both diagnostic approaches are thought to be as useful as RTE.

B Recommended imaging techniques

It supports "no manual compression" and "minimal vibration," but it does not support "significant compression."

C Displayed ROI

This method is dependent on the size of the displayed ROI since it is a relative assessment. For the size of the displayed ROI, the maximum width should be selected for the horizontal direction, and for the depth direction it is recommended that the ROI include the area from the subcutaneous tissue to adipose tissue and mammary tissue, and not the pectoralis major muscle and bones (ribs), in order to acquire an abundance of strain information.

D Imaging time

The color or white image is visualized immediately after the initial vibration (1-2 sec) for both the

elastography color image display and gray-scale image display. However, it is important to continue imaging until the color of the entire target is completely stable to acquire a reliable image, so you should spend plenty of time at first.

An indicator referred to as the compression bar is displayed at the right of the image (under the color bar). This is calculated based on two parameters, i.e., the received strain data volume and the variability. A stable image has been acquired when the color of the compression bar has changed from gray to green, and when the length of the bar is stable.

Since this application allows analysis of oscillatory waveforms retrospectively, it is possible to calculate confidence levels after the fact by means of waveform analysis, but it is envisioned that examinations will end with imaging alone in actual clinical settings due to time constraints, so imaging should always be continued until the color of the entire target is completely stable. In this sense, the color image display, which is more delicate in terms of the color of the entire target stabilizing, may be more stable and accurate.

E Images and pathological features (Fig.33a, b, c)

F Outstanding issues

Since deep lesions cannot be adequately vibrated with "no manual compression" or "minimal vibration," it may be difficult to visualize fairly deep lesions on elastography images.

The rendering may differ from probe to probe, necessitating adjustment of the application.

G Summary

Since Philips Healthcare's elastography permits gray-scale display in addition to color display, diagnosis is possible with the Tsukuba score, the strain ratio, or E/B ratio. Moreover, raw data are stored, allowing for a variety of analyses, and it includes tools for evaluating the accuracy of elastography and developing new diagnostic approaches. However, the application designed for breast imaging only supports Strain Elastography, with an emphasis on "no manual compression." It does not support Shear Wave Elastography. Philips Healthcare's elastography supports Shear Wave Elastography for the liver, and various diagnostic approaches are already possible. Its utility would improve if it were possible to use Shear Wave Elastography to depict deep lesions for which "no manual compression" is not suited.

6-1-c Strain Elastography : GE Healthcare

A Diagnostic approach and evidence

GE Healthcare's elastography uses a revised direct strain method, in which the signals before and after compression are divided into microregions for comparison, and direct strain is calculated based on the compression rate of waveforms in the regions.

However, this method is similar to RTE in that strain is calculated, and it is recommended that a diagnosis be made with the elasticity score (Tsukuba score) and the elasticity index and ratio using elastography color images. Basically, the ratio of the stiffness of two target ROIs is expressed numerically, like the strain ratio, but the definition of the numerical value differs slightly, so the difference will be explained. To calculate the elasticity ratio, the elasticity index of each target ROI is first calculated. Assuming that the average strain in the displayed ROI is 1.0, the elasticity index is a value expressed from 0 to <1.0 for strain larger than the average, and from 1.0 to 6.0 for strain smaller than the average. $E2/E1$, the ratio of $E1$ and $E2$, which are the elasticity indices of the two target ROIs, is calculated as the elasticity ratio. Like kPa and Vs, these do not directly express stiffness, but it has been experimentally confirmed that the difference in the stiffness can be obtained as the index difference in a phantom with different stiffness in the

target and the surrounding tissue.

Figure 34 is an example of the time series analysis function for elasticity index (graph upper row) and elasticity ratio (lower row) after setting a reference target ROI (yellow) in the fat layer and three target ROIs (cyan, red, green) in the mass image.

There have been no reports of any prospective studies to date, but its utility based on experience has been reported.

B Recommended imaging techniques

In terms of the initial compression, rather than acquire a B-mode image, perform imaging with "minimal vibration" by means of slight compression with the probe, or with "significant compression." Since the compression rate of waveforms before and after compression is evaluated, "no manual compression," which involves no movement of the probe at all, is not recommended. Imaging is normally performed with "minimal vibration," but good images can be acquired when "significant compression" is used in the case of deep lesions.

As for the direction of the compression, it is recommended that imaging take place when the level of the quality graph or quality bar, which is shown on the display and serves as a guide to compression status, is as high as possible and stable, with the direction of the compression being kept vertical to the probe surface (Fig. 35).

C Displayed ROI

Since a relative mapping mode is used, a displayed ROI size that is suitable for acquiring strain information from both the mass and the surrounding tissue is preferable. Set the ROI so that the ratio of the area of the mass to the area of the surrounding tissue is not 1:1 but rather includes more of the surrounding tissue. The horizontal direction should generally be on the wide side, but if it is difficult to apply uniform compression with the end of the probe and B-mode is degraded, it should be set in a way that avoids that part. Set the depth direction so that the ROI includes the area from the subcutaneous tissue to the adipose tissue and mammary tissue, and not lungs and bones (ribs). Even if a part of the pectoralis major muscle is included, there is no problem.

D Imaging time

A color image is visualized immediately after the initial vibration (1-2 sec), but imaging needs to continue until the color of the entire target is completely stable in order to acquire reliable measurement results. The time required will get shorter as the operator's skill improves, but it is important to continue imaging until the color of the entire target is completely stable at first.

E Images and pathological features

Like RTE, the most useful point to remember in clinical practice is that it yields information that can differentiate cysts, fibroadenomas, and fat islands (adipose tissue in the mammary gland) based on mass images in patients recalled for closer examination. It is also a source of information for further confirming that a malignant tumor is a hard tumor.

A case of scirrhous carcinoma is presented in Fig. 36. From left to right are B-mode, elastography, and macroscopic specimen images.

Sites showing green lines are sites where tumor and tumor progression were observed. We can see that the spread of hard sites is expressed by elastography for the most part.

F Outstanding issues

Since it is a relatively new application, there are reports of its utility based on experience, but there have

been no reports of prospective studies to date. We hope that a multicenter prospective study will be conducted in the future.

G Summary

GE Healthcare's elastography is Strain Elastography in which biological tissue is compressed and relaxed with a probe to evaluate the resulting strain. Using the revised direct strain method for the detection algorithm, it displays real-time 2D images. It also has a function that provides feedback to the operator by evaluating the quality (reliability of data) of the acquired images to reduce dependence on the skill of the operator with respect to the compression operation.

In terms of measurement functions, it can measure semiquantitative numeric information (elasticity index) in the target ROI and its ratio. In addition, it has an analysis function that provides a time series graph along with acquired image quality. A standout feature is the ability to store images as raw data and remeasure images and perform analysis after examination completion.

6-1-d Strain Elastography: Toshiba Medical

A Diagnostic approach and evidence

The operating procedure and vibration method differ depending on the model in the case of Toshiba Medical Systems' unit.

In the case of the Aplio XG and MX, images displayed in real time are so-called tissue Doppler images (TDI) colored with the tissue velocity component. In this case, it is recommended that compression/vibration be applied somewhat robustly in order to acquire strain images with certainty. It is necessary to switch to the strain image display after compression/vibration has stabilized.

In the case of the Aplio 500, 400, and 300, on the other hand, strain images can be observed in real time. In addition, the relative strain ratio (SR) can be observed by placing the target ROI on the target site. Moreover, since tissue Doppler shift is used, relatively deep areas can be observed.

At present, there are reports of its utility based on experience¹⁷⁻¹⁸⁾, but there have been no reports of prospective studies.

Elasto-Q (elastography quantification)

The standout feature of Toshiba's system is the ability to perform elastography quantification (statistical calculation and tissue strain quantification) by inputting raw data collected from the main ultrasound unit into an offline workstation. By placing a region of interest with an arbitrary shape at an arbitrary location, the accumulated strain volume is displayed in a graph form, and the strain rate (percentage) and strain ratio are calculated and displayed. It is also possible to automatically track this region of interest in the depth direction in concert with tissue movement. Analysis with this type of workstation allows confirmation of reproducibility and reliability between the operator and the reader, and may contribute to the standardization of ultrasound elastography.

B Recommended imaging techniques

When acquiring elastography images, the system control settings should be suitable to that task.

Use "significant compression" for the vibration method, and perform imaging from near to deep. Applying deep compression is particularly useful for observing deep lesions. However, it should be noted that a color image will not be accurately displayed if the compression is too fast and deep as aliasing will occur. In addition, vibration below "significant compression" can be applied to improve the resolution. Make sure that the probe does not deviate vertically in the scanning direction and tilt direction during compression. At a

relatively slow speed, repeat very mild compression/release 3-5 times in intervals of 1-2 seconds. Compression/release is considered to be appropriate when the velocity profile displayed at the bottom of the display is nearly sinusoidal, and the release (lower side) is considered to be closer to the actual strain value than the compression (upper side).

C Displayed ROI

Since strain displacement is relatively expressed within the range of the displayed ROI, the displayed ROI should be set to include a wide area from subcutaneous tissue to a part of the pectoralis muscle, and the horizontal direction should be set to the maximum width. The ribs and lungs should not be included.

D Imaging time

Color display is achieved immediately after the initial vibration (after 1-2 sec), but it is important to continue imaging until the color in the displayed ROI is completely stable in order to acquire reliable measurement results.

Strain images are shown as color images according to a strain color scale, with blue being hard tissue, green being tissue of average stiffness, and red being soft tissue based on the degree of strain in the tissue.

E Images and pathological features (Fig. 39a-c)

F Outstanding issues

After a series of investigations, it was found that strain images acquired using TDI are equivalent to images obtained with other compression methods. On the other hand, the direction of strain that can be detected is that in the depth direction of the ultrasound raster pattern as a result of use of Doppler. Strain perpendicular to the ultrasound raster pattern cannot be captured. At the same time, attention should be paid to aliasing in instances where the compression velocity may get too high (when compression is fast or compression is deep). Understanding this information and setting the appropriate parameters according to the system and probe are both important and a challenge.

G Summary

At the present time, units from Toshiba Medical Systems that support elastography are the old Aplio series (Aplio XG and MX) and the new Aplio series (Aplio 500, 400, and 300). The description in this report has focused on the Aplio series that is currently available. It is hoped that they will support "minimal vibration" and "no compression" in the future by optimizing the system configuration.

6-1-e Strain Elastography : SIEMENS (eSie Touch™ Elasticity Imaging)

A Diagnostic approach and evidence

The diagnostic approach used in eSie Touch elasticity imaging is equivalent to the color image evaluation with RTE. Although it is the same as RTE in that transparent colors are superimposed on monochrome B-mode images for color display, it should be noted that the coloration is opposite that of RTE. Namely, hard tissue is displayed as red to more easily grab the observer's attention, while soft tissue is displayed as blue. A feature for reversing the coloration is also provided (Fig. 40 & 41).

In addition, a mode for displaying strain images as gray-scale images without color coding is also provided. In this mode, the strain image is displayed independently next to the B-mode image without superimposition. While the color display mode always entails observation with the strain image and B-mode image integrated, the gray-scale display mode is suitable for evaluating the strain component in isolation, making it a convenient display method for measuring the EI/B ratio (Fig. 42).

Hall et al.¹⁹⁾ reported the sensitivity of 100% and the specificity of 75.4% when the EI/B ratio of 1.2 or

higher was considered malignant. Barr et al²⁰⁾ reported the sensitivity of 100% and the specificity of 95% when the EI/B ratio of <1.0 was considered benign and the EI/B ratio of 1.0 or higher was considered malignant in 123 cases diagnosed by biopsy.

Switching from a color display to the gray-scale display is simply a matter of flipping a switch, and it can also be changed after construction of the strain image.

B Recommended imaging techniques

Strain images are constructed using tissue strain caused by minute movements such as the patient's respiratory movement or heartbeat. Think about keeping the probe in place rather than applying pressure. This minimizes inconsistent results caused by differences in the skill of the operator during compression. In addition, an indicator (Quality Factor: QF) that shows the reliability of the imaging is provided to make it easier to acquire stable images. This indicator instantly displays the stability of information on the imaged stiffness in the form of a number (0-100%). A higher number indicates more reliable imaging. The number to aim for should be at least 60%.

C Displayed ROI

With this system, the computation for constructing strain images is always carried out for the entire B-mode image regardless of the size of the displayed ROI. As such, there is no need to take into account the size of the ROI or the position relative to the pectoralis major muscle when configuring the displayed ROI. In addition, the displayed ROI indicates the range of tissue strain information to be displayed; therefore, the position and size can be changed after a strain image is constructed.

D Imaging time

A strain image can be instantaneously displayed by placing the probe on the skin. It may take 2-3 seconds before the stiffness information stabilizes and the QF reaches at least 60.

F Outstanding issues

A diagnosis based on the E/B ratio obtained on gray-scale display is common overseas, but there is no evidence about this in Japan. Evaluation similar to that with RTE is believed to be possible using the color display, but there is no evidence from comparative studies.

G Summary

Strain Elastography is easily achieved without compression. Diagnosis using the E/B ratio obtained on a gray-scale display is widely used overseas, but it has not caught on in Japan. As the evaluation method used in the color display mode is thought to be equivalent to the evaluation of color images with RTE, it is a technique that can be used for routine examinations.

6-2 ARFI: SIEMENS (VTI: Virtual Touch™ Imaging)

A Diagnostic approach and evidence

Virtual Touch Imaging (VTI) is a method in which tissue displacement generated by the action of acoustic radiation force is detected and imaged. A gray-scale display is employed, with soft areas expressed as white and hard areas as black. The image is displayed independently next to the B-mode image without superimposition. A color display feature in which the image is superimposed on the B-mode image is also provided (Fig. 43).

Tozaki et al. investigated 40 cases, classifying lesions with a white interior as pattern 1 and black (or gray) interior as pattern 3, and those that could not be visualized as pattern 2. Three lesions were pattern 1 and seven lesions were pattern 2, all of which were benign. The breakdown was 18 cases with benign lesions and

22 cases with malignant tumors. The remaining eight benign lesions and 22 malignant lesions were assessed as pattern 3. Assuming patterns 1 and 2 to be benign and pattern 3 to be malignant, the sensitivity was 100% and the specificity 56%. The specificity was low, with 44% of benign lesions exhibiting pattern 3, but no malignant lesions were classified as pattern 1 or pattern 2, resulting in a negative predictive value of 100%⁽²¹⁾.

VTI can also be used to measure the horizontal size of a tumor and differentiate whether it is benign or malignant by comparing it with the B-mode image. Since a shadow is often cast posteriorly, the horizontal size is measured without using the vertical size. Another standout feature is that the internal structure can be visualized well. The interior of hard tissue, in particular, can be depicted well. It may be that it is capable of imaging differences in the tissue structure such as the liquid component, solid component, and septiform structure⁽²²⁾. In the case of manual Strain Elastography, it is often not possible to depict the state of the interior of a tumor because a hard tumor will move as one as a result of the external force.

B Recommended imaging techniques

Since tissue compression takes place automatically by the application of ARFI, the probe is kept still on the body surface, and one-shot imaging is displayed by simply pushing the trigger button. Therefore, there is no need for any special skill, making it less dependent on the operator. In the tissue where the push pulse attenuates greatly, however, images may be incomplete due to the inability to acquire a signal from within the tissue.

C Displayed ROI

The maximum depth of the displayed ROI is 6 cm, and the width can be expanded to the full B-mode display area, but it should not be made unnecessarily large relative to the size of the mass. In addition, it is focus dependent, so the focus should be set near the inferior extremity of the mass.

D Imaging time

An elastography image (still image) is obtained within 1 second after pushing the trigger button. A programmed cool-down period (2-3 seconds) will then start, during which it will not be possible to push the trigger.

F Outstanding issues

The choice of probe for breast imaging is limited to a linear probe (9L4). As such, it is hoped that a greater variety of probes will become available, such as those with a higher frequency and better spatial resolution.

G Summary

In the case of eSie Touch elasticity imaging, it may take 2-3 seconds before the stiffness information stabilizes and the QF reaches at least 60, but VTI is easier to use because a stable elastography image can be acquired within 1 second. Another standout feature is that the internal structure can be visualized well. Since absolutely no manual compression is necessary, the reproducibility is good and there is little measurement error between examiners, and although there is no evidence, the evaluation method used in the color display mode is thought to be equivalent to the evaluation of color images with RTE. Therefore, it is a technique that even a beginner can use for routine examinations.

6-3-a Shear Wave Elastography : SIEMENS (VTQ: Virtual Touch™ Quantification)

A Diagnostic approach and evidence

Although it is not imaging, it is a feature in which shear waves are generated using ARFI and their velocity is measured to quantitatively measure local stiffness. It is often used for diagnosis of liver fibrosis in

chronic hepatitis²⁵⁻²⁹).

Absolute stiffness can be measured, and it can yield information that is useful for differentiating breast tumors (Fig. 44).

Tozaki et al. reported the use of shear wave velocity (Vs) for differentiating benign and malignant lesions. The Vs of malignant lesions tended to be higher, but measurement was often impossible when the target ROI was placed at the center of the tumor. When they placed the target ROI at the margin where measurement was almost certainly possible, the average Vs of 83 malignant lesions was 5.00 m/s, which was significantly higher ($p < 0.001$) than the average Vs of 70 benign lesions, which was 2.81 m/s²²).

Combination of VTI and VTQ for tumor analysis

VTI and VTQ can be used independently for differential diagnosis, but there is significant overlap between no malignancy and malignancy. However, it was reported that the sensitivity of 91%, specificity of 93%, and accuracy of 92% were achieved when VTI was initially used to select clear no malignancy and clear malignancy, followed by the application of VTQ to select the remaining lesions with intermediate properties, with a cut-off of 3.59 m/s²²).

B Recommended imaging techniques, C Displayed ROI, D Imaging time

The measured Vs [m/s] instantaneously appears on the screen simply by selecting the target ROI and pushing the button. The size of the target ROI is fixed at 5 mm x 5 mm, and the maximum measurable depth is 4 cm (Fig. 42). Vs can be measured instantaneously, but there is a cool-down period (2-3 seconds) after the measurement is displayed. If you would like to continue measuring, you have to wait for the cool-down period to end.

• Problem of unmeasurable cases (X.XX)

When the reliability of the measurement is low, Vs=X.XX m/s is displayed, indicating that the measurement is not possible.

It is said that Vs=X.XX m/s is displayed about 80% of the time when measuring the interior of scirrhous carcinomas²³).

In these unmeasurable cases, the measurement is almost always possible by moving the ROI to the surrounding area (Fig. 45).

• Effects of compression

It is known that Vs increases when strong compression is applied, but it has been reported that the variation is not significant enough to change the diagnosis even if the degree of compression differs during a regular examination²⁴).

E Images and pathological features (Fig. 45a-d)

F Outstanding issues

The choice of probe for breast imaging is limited to a linear probe (9L4). As such, it is hoped that a greater variety of probes will become available, such as those with a higher frequency and better spatial resolution.

G Summary

Measurement is easy even for beginners, and it is effective because there is evidence supporting the assessment of no malignancy/malignancy. Since slight variability arises in measurements resulting from heterogeneity of the tissue being measured, the average of about three measurements should be used. It is hoped that many articles on this will be published, and that it will become an established examination method.

6-3-b Shear Wave Elastography : SIEMENS (VTIQ: Virtual Touch™ IQ)

A Diagnostic approach and evidence

This is a feature in which imaging is performed by generating shear waves using ARFI and measuring their velocity. It has only been available in Japan since March 2012, so clinical experience with it is still limited. It combines imaging that shows the distribution of stiffness and the function for measuring absolute stiffness at an arbitrary point in the ROI to yield information that is useful for differentiating breast tumors. The evaluation method is the same as that for VTI and VTQ.

B Recommended imaging techniques, C Displayed ROI, D Imaging time

1) A one-shot shear wave image instantaneously appears on the screen simply by selecting the displayed ROI and pushing the button. Therefore, there is no need for any special skill, making it less dependent on the operator.

Although it is the same as RTE in that transparent colors are superimposed on monochrome B-mode images, the coloration is opposite that of RTE. Namely, hard tissue is displayed as red to more easily grab the observer's attention, while soft tissue is displayed as blue.

The maximum size of the displayed ROI is 25 mm (length) x 38 mm (width), and the maximum depth setting is 62 mm.

2) Measurement of shear wave velocity

When the 2mm-square measurement cursor (target ROI) is placed on a lesion after the image is acquired, the shear wave velocity at that location can be gauged numerically. It also comes with a quality mode in which the image is displayed after calculating the quality of the shear wave waveform based on the noise level of the received signal and the amplitude size. This allows the operator to determine artifacts in shear wave images, improving the measurement reliability (Fig. 46 & 47). In some cases, having the patient hold her breath may be effective.

E Images (Fig.46a, b, Fig.47a-c)

F Outstanding issues

The choice of probe for breast imaging is limited to a linear probe (9L4). As such, it is hoped that a greater variety of probes will become available, such as those with a higher frequency and better spatial resolution. Evidence is limited as it has not been long since this technology was commercialized. Therefore, cases need to be gathered and studied.

G Summary

It is possible to measure Vs with VTIQ even in cases in which it cannot be measured using VTQ. Moreover, the inclusion of the quality mode makes distinguishing artifacts easy, improving the reliability of measurements. It is hoped that many articles on this will be published, and that it will become an established examination method.

6-3-c Shear Wave Elastography : SuperSonic Imagine

<Principle>

When the focused ultrasound beam is transmitted with the probe, the tissue is displaced posteriorly, and shear waves are generated when the restorative force of the tissue propagates horizontally. Shear waves with a conical surface form by continuously transmitting the ultrasound beam to different depths in the tissue (Fig. 48). The propagation of generated shear waves takes place by simultaneously using all transducers to send and receive ultrasonic waves, and moving images are acquired by repeating this at high speed. Velocity is calculated based on the distance shear waves move and the duration obtained from the moving images. The relationship between Young's modulus (E) and shear wave propagation speed (c) can be expressed as $E=3\rho c^2$ (ρ is tissue density; It can be approximated as 1 *in vivo*), and the calculated Young's modulus (E) is thought to express tissue elasticity. Since the propagation speed of shear waves is fast in hard tissue and slow in soft tissue, it is possible to calculate tissue elasticity based on the velocity and display the kilopascal unit (kPa)*. The elasticity value is converted to a color code and displayed as a color map by superimposing it on the B-mode image in real time³⁰. Normally, lesions with a low (soft) elasticity value are displayed as blue, and lesions with a high (hard) elasticity value are displayed as yellow-red.

*The unit (kPa or m/s) used differs depending on the country.

A Diagnostic approach and evidence

It has been pointed out that the strength of probe compression and color judgments are influenced by the operator's experience³¹⁻³² in the case of strain elastography, but in the case of SWE, diagnostic imaging with high reproducibility is possible without relying on the skill of the operator, because tissue elasticity can be evaluated with the probe in a stationary position and without tissue compression³³⁻³⁴.

As for reports related to quantitative values that express tissue elasticity, using a mean tissue elasticity of 50 kPa as the cut-off value for distinguishing no malignancy and malignancy, Evans et al.³⁵ reported the sensitivity of 97%, specificity of 83%, positive predictive value (PPV) of 88%, negative predictive value (NPV) of 95%, and accuracy of 91%, but no significant difference was found versus BI-RADS alone. Chang et al.³⁶ reported that the diagnostic performance was best when a mean tissue elasticity of 80.17 kPa was used as the cut-off value, which resulted in the sensitivity of 88.8% and the specificity of 84.9%, and the area under the receiver operating characteristic curve (AUC) was 0.898 when assessed with BI-RADS alone, which improved to 0.982 when combined with SWE. In a large-scale multicenter study (The BE1 Multinational Study)³⁷, AUC was 0.950 when lesions classified as BI-RADS category 3 and higher were assessed with BI-RADS alone, but it increased to 0.962 when combined with SWE. In the case of BI-RADS category 3 and 4a lesions, in particular, the specificity increased from 61.1% to 78.5% without lowering the sensitivity, suggesting that unnecessary biopsies can be avoided. Evans et al.³⁸ investigated the association between tissue elasticity and histopathological factors. They suggested that tissue elasticity was high in lesions with a large tumor diameter, high tissue grade, the presence of lymph node metastasis, and vascular invasion, with the diameter of invasion, in particular, affecting tissue elasticity.

On the other hand, even if quantitative measurement is not done, it has been reported that diagnosis is possible by visually evaluating the color map since the color image yielded is based on the measurement of Young's modulus³⁹⁻⁴⁰.

Tozaki et al.³⁹ classified displayed color maps into four patterns (Fig. 49). When they regarded lesions displayed homogeneously blue (pattern 1) and vertical stripe pattern artifacts (pattern 2) as benign lesions, and a localized colored area at the margin of the lesion (pattern 3) and heterogeneously colored areas in the

interior of the lesion (pattern 4) as malignant lesions, they reported the sensitivity of 91.3% and the specificity of 80.6%. In the case of BI-RADS category 4 lesions, in particular, they reported that the addition of pattern classification resulted in the sensitivity, specificity, and accuracy of 91.3%, 87.1%, and 90%, respectively, which was an increase, when B-mode was used alone.

The visual pattern classification of the color map and the quantitative value using the SWE are useful to differentiate between benign and malignant. But there are some cases of DCIS and small invasive cancer, despite the malignant lesion, which are coded in blue homogeneously (Figure.50 Blue Cancer), it is important to evaluate together with the findings of B-mode images.

B Recommended imaging techniques

Place the probe vertically to the lesion being measured and visualize it in B-mode. Since ultrasound is used to detect shear waves, create a clear B-mode image before switching to the SWE mode. In the SWE mode, it is important to handle the probe softly, slowly, and smoothly.

It is recommended that the default 180 kPa be used for the color scale.

Quantitative tissue elasticity values can be measured by using the target ROI, which is called Q-Box™, at an arbitrary site on the color map image obtained. The size of this target ROI is normally 2 mm, and elasticity is measured at the location that is displayed as the hardest in the lesion or at the border (Fig. 51). Mean elasticity, maximum elasticity, minimum elasticity, and standard deviation (SD) are displayed at the right of the screen.

The tissue elasticity reading may be high due to excessive compression even if the tumor is soft (Fig. 52). If there are areas other than the lesion that are displayed as yellow to red in the displayed ROI, it means that compression is too strong and needs to be decreased⁴³⁻⁴⁴).

C Displayed ROI

The size of the displayed ROI should be adjusted to match the tumor diameter, but it should not be any larger than necessary as the frame rate will suffer. It can usually be left at the default setting.

D Imaging time

After starting imaging, stop the image after the color display was stable for 2-3 seconds, and measure and record qualitative values. The time it takes for the color to stabilize will differ from case to case, but it is important to move the probe as little as possible to stabilize the image more quickly, and having the patient hold her breath may be effective in some cases. The time required will get shorter as the operator's skill improves.

E Images and pathological features (Fig.53a, b, Fig.54a-c, Fig.55a-c)

F Outstanding issues

- In general, malignant lesions are histopathologically hard heterogeneous lesions due to a high cell density and involvement of lymphocytic infiltration and necrosis⁴³), but there are malignant lesions that are judged to be soft masses (Blue Cancer). Evans et al³⁵⁾ reported that there are benign lesions that are hard and malignant lesions that are soft.
- There is a limit to the depth that can be measured in connection with the acoustic power. As such, there are cases that cannot be measured when the lesion is deep.
- As this is a new technology that was commercialized only fairly recently, there is a global paucity of evidence in the form of journal articles, etc., and diagnostic criteria have not been established. More cases need to be gathered and studied.

G Summary

Indication: It is indicated for determining the need for biopsy in patients with a breast mass.

Merit: As the tissue compression is not needed, highly reproducible diagnostic imaging is possible without dependence on the operator's skill.

Issues: Malignant lesions are sometimes displayed as soft.

Cases need to be collected and studied as there is a paucity of evidence.

Examination tip/precaution: It is important to handle the probe softly, slowly, and smoothly without applying compression.

7. Conclusion

Elastography is already adequate to withstand clinical use, or it has become a necessary tool, in the field of breast ultrasound in Japan. However, the features of elastography systems differ greatly from system to system, making it difficult to use them in the most appropriate manner.

In the present report, the state of breast ultrasound elastography in 2013 was organized, and classification by vibration energy method and imaging method, and classification by clinical diagnosis/reading method, were presented.

In addition, the features of the systems from leading manufacturers Hitachi Aloka Medical, Siemens, GE Healthcare, Philips Healthcare, Toshiba Medical, and SuperSonic Imagine were explained by contrasting them in terms of evidence and recommended diagnostic approaches, settings and tips for taking good images, and representative images and pathological features useful for diagnosis. It is hoped that this report will give you an adequate understanding of the features of each elastography method, allow you to carry out proper imaging and diagnosis, and help you realize that elastography is truly a clinically useful tool.

Reports and research trends as of 2013 suggest that Strain elastography tends to be developed and used for predicting pathological features based on the distribution of stiffness, and Shear wave elastography for quantitatively measuring the stiffness of masses. However, the current focus of many prospective studies is to improve specificity and lower the recall rate by using the BI-RADS criteria plus elastography as the endpoint⁴⁵⁾.

As described in this report, we are beginning to see reports about the utility of elastography for presumptive diagnosis of the histopathology of masses, above and beyond its utility for assessing the therapeutic effect of chemotherapy, its utility for identifying lesions that do not present as a mass, and its utility for differentiating no malignancy and malignancy, and more new uses may emerge in the future.

Elastography systems and the applications themselves also continue to evolve, and new tools and new evidence are likely to emerge. We anticipate that the direction of development, imaging methods, and diagnostic approaches will change and fragment in the future.

It appears that elastography has already become an essential medical tool in the field of breast imaging.

8. Acknowledgement

We would like to express our deep gratitude to Dr. Mitsuhiro Tozaki (Kameda Medical Center), Dr. Ayumi Izumori (Takamatsu Heiwa Clinic), Dr. Atsuo Kawamoto (Tokyo Medical University Hospital), Mr. Naoyuki Murayama (Hitachi Aloka Medical), Mr. Masahiro Saito (Siemens), Mr. Shunichiro Tanigawa (GE Healthcare), Mr. Jun Murakami (Philips Healthcare), Mr. Masahiko Yano (Toshiba Medical), and Mr. Teruhiro Yoshida (Canon Lifecare Solutions), Chihoko Yamagata (Kawasaki Welfare School) for their cooperation and advice, and for providing images for this report.

REFERENCE

- 1) Ueno E, Tohno E, Bamber JC, et al. Dynamic tests in real-time breast echography. *Ultrasound Medical Biological* 1988;14:53.
- 2) Ophir J, Caspedes I, Ponnekanti H, et al. Elastography: a quantitative method for imaging the elasticity of biological tissues. *Ultrasonic Imaging* 1991;13:111-34.
- 3) Nakashima K. Report of achievements from quality control research group. *Journal of Breast and Thyroid Sonology* 2013;12(1):61.
- 4) Japan Association of Breast and Thyroid Sonology. Guideline of breast ultrasound diagnosis 2nd edition
- 5) Itoh A, Ueno E, Tohno E, et al. Breast disease: clinical application of US elastography for diagnosis. *Radiology* 2006;239(2):341-50.
- 6) Raza S, Odulate A, Ong EM, et al. Using real-time tissue elastography for breast lesion evaluation. *J Ultrasound Med* 2010;29(4):551-63.
- 7) Ueno E, Umemoto T, Bando H, et al. New quantitative method in breast elastography: fat-lesion ratio (FLR) [abstract]. In: *Proceedings of the Radiological Society of North America Scientific Assembly and Annual Meeting*. Oak Brook, IL: Radiological Society of North America; 2007. p. 697.4th
- 8) Farrokhi A, Wojcinski S, Degenhardt F. Diagnostic value of strain ratio measurement in the differentiation of malignant and benign breast lesions. *Ultraschall Med* 2011;32(4):400-5.
- 9) Alhabshi SM, Rahmat K, Abdul Halim N, et al. Semi-quantitative and qualitative assessment of breast ultrasound elastography in differentiating between malignant and benign lesions. *Ultrasound Med Biol* 2013;39(4):568-78.
- 10) Jung Min Chang, Woo Kyung Moon, Nariya Cho, et al. Breast mass evaluation: factors influencing the quality of US elastography. *Radiology* 2011;259:59-64.
- 11) Nakashima K, Moriya T. Comprehensive ultrasound diagnosis for intraductal spread of primary breast cancer. *Breast Cancer* 2012;31:.
- 12) Adamietz BR, Kahmann L, Fasching PA, et al. Differentiation between phyllodes tumor and fibroadenoma using real-time elastography. *Ultraschall Med* 2011;32(Suppl 2):E75-9.
- 13) Hayashi M, Yamamoto Y, Ibusuki M, et al. Evaluation of tumor stiffness by elastography is predictive for pathological complete response to neoadjuvant chemotherapy in patients with breast cancer. *Ann Surg Oncol* 2012;19(9):3042-9.
- 14) Wojcinski S, Dupont J, Schmidt W, et al. Real-time ultrasound elastography in 180 axillary lymph nodes: elasticity distribution in healthy lymph nodes and prediction of breast cancer metastases. *BMC Medical Imaging* 2012, 12:35. doi:10.1186/1471-2342-12-35
- 15) Lakhani SR, Ellis IO, Schnitt SJ, et al. WHO classification of tumours of the breast 4th edition, 2012
- 16) Stachs A, Hartmann S, Stubert J, et al. Differentiating between malignant and benign breast masses: factors limiting sonoelastographic strain ratio. *Ultraschall Med* 2013;34(2):131-6.
- 17) Thomas A, Warm M, Hoopmann M, et al. Tissue Doppler and strain imaging for evaluating tissue elasticity of breast lesions. *Acad Radiol* 2007;14(5):522-9.
- 18) Fischer T, Peisker U, Fiedor S, et al. Significant differentiation of focal breast lesions: raw data-based calculation of strain ratio. *Ultrschall in der Medizin* 2012;33(4):372-9.
- 19) Hall TJ, Zhu Y, Spalding CS, et al. Ultrasound palpation imaging as a tool for improved differentiation among breast abnormalities [abstract]. *Radiology* 2001;221(suppl):697.

- 20) Barr RG. Real-time ultrasound elasticity of the breast: initial clinical results. *Ultrasound Q* 2010;26:61-6.
- 21) Tozaki M, Isobe S, Yamaguchi M, et al. Ultrasonographic elastography of the breast using acoustic radiation force impulse technology: preliminary study. *Jpn J Radiol* 2011;29(6):452-6.
- 22) Tozaki M, Isobe S, Sakamoto M. Combination of elastography and tissue quantification using the acoustic radiation force impulse (ARFI) technology for differential diagnosis of breast masses. *Jpn J Radiol* 2012;30(8):659-70.
- 23) Tozaki M, Saito M, Joo C, et al. Ultrasonographic tissue quantification of the breast using acoustic radiation force impulse technology: phantom study and clinical application. *Jpn J Radiol* 2011;29(8):598-603.
- 24) Tozaki M, Isobe S, Fukuma E. Preliminary study of ultrasonographic tissue quantification of the breast using the acoustic radiation force impulse (ARFI) technology. *Eur J Radiol* 2011;80(2):e182-7.
- 25) Friedrich-Rust M, Wunder K, Kriener S, et al. Liver fibrosis in viral hepatitis: noninvasive assessment with acoustic radiation force impulse imaging versus transient elastography. *Radiology* 2009;252:595-604.
- 26) Lupsor M, Badea R, Stefanescu H, et al. Performance of a new elastographic method (ARFI technology) compared to unidimensional transient elastography in the noninvasive assessment of chronic hepatitis C: preliminary results. *J Gastro Intest Liver Dis* 2009;18:303-10.
- 27) Takahashi H, Ono N, Eguchi Y, et al. Evaluation of acoustic radiation force impulse elastography for fibrosis staging of chronic liver disease: a pilot study. *Liver Int* 2010;30:538-45.
- 28) Gallotti A, D'Onofrio M, Mucelli RP. Acoustic radiation force impulse (ARFI) technique in ultrasound with Virtual Touch tissue quantification of the upper abdomen. *Radiol Med* 2010;115:889-97.
- 29) Yoneda M, Suzuki K, Kato S, et al. Nonalcoholic fatty liver disease: US-based acoustic radiation force impulse elastography. *Radiology* 2010;256:640-7.
- 30) Tanter M, Bercoff J, Athanasiou A, et al. Quantitative assessment of breast lesion viscoelasticity: initial clinical result using supersonic shear wave imaging. *Ultrasound Med Biol* 2008;34:1373-86.
- 31) Burnside ES, Hall TJ, Sommer AM, et al. Differentiating benign from malignant solid breast masses with US strain imaging. *Radiology* 2007;245:401-10.
- 32) Regner DM, Hesley GK, Hangiandreou NJ, et al. Breast lesions: evaluation with US strain imaging - clinical experience of multiple observers. *Radiology* 2006;238(2):425-37.
- 33) Athanasiou A, Tardivon A, Tanter M, et al. Breast lesions: quantitative elastography with supersonic shear imaging - preliminary results. *Radiology* 2010;256(1):297-303.
- 34) Cosgrove DO, Berg WA, Doré CJ, et al. Shear wave elastography for breast masses is highly reproducible. *Eur Radiol* 2012;22(5):1023-32.
- 35) Evans A, Whelehan P, Thomson K, et al. Quantitative shear wave ultrasound elastography: initial experience in solid breast masses. *Breast Cancer Res* 2010;12(6):R104.
- 36) Chang JM, Moon WK, Cho N, et al. Clinical application of shear wave elastography (SWE) in the diagnosis of benign and malignant breast diseases. *Breast Cancer Res Treat* 2011;129(1):89-97.
- 37) Berg WA, Cosgrove DO, Doré CJ, et al. Shear-wave elastography improves the specificity of breast US: the BE1 multinational study of 939 masses. *Radiology* 2012;262(2):435-49.
- 38) Evans A, Whelehan P, Thomson K, et al. Invasive breast cancer: relationship between shear-wave elastographic findings and histologic prognostic factors. *Radiology* 2012;263(3):673-7.

- 39) Tozaki M, Fukuma E. Pattern classification of shear wave elastography images for differential diagnosis between benign and malignant solid breast masses. *Acta Radiol* 2011;52:1069-75.
- 40) Hye Mi Gweon, Ji Hyun Youk, Eun Ju Son, et al. Visually assessed colour overlay features in shear-wave elastography for breast masses: quantification and diagnostic performance. *Eur Radiol* 2012 [Epub ahead of print].
- 41) Barr RG. Sonographic breast elastography: a primer. *J Ultrasound Med* 2012;31(5):773-83.
- 42) Barr RG, Zhang Z. Effects of precompression on elasticity imaging of the breast: development of a clinically useful semiquantitative method of precompression assessment. *J Ultrasound Med* 2012;31(6):895-902.
- 43) Stavros AT, Thickman D, Rapp CL, et al. Solid breast nodules: use of sonography to distinguish between benign and malignant lesions. *Radiology* 1995;196:123-34.
- 44) Sadigh G, Carlos RC, Neal CH, et al. Accuracy of quantitative ultrasound elastography for differentiation of malignant and benign breast abnormalities: a meta-analysis. *Breast Cancer Res Treat* 2012;134(3):923-31.

Figure Legend

Figure 1

Equipment with an elastography application.

Figure 2

Get a good B-mode image to get a good elastography image.

Figure 3

Keep the angle of the probe perpendicular to the skin

Figure 4

Probe orientation in the radial scan line should be similar to the breast duct

Figure 5

No manual compression

Figure 6

Strain elastography obtained by no manual compression.

Figure 7

Minimal vibration

Figure 8

Strain elastography obtained by minimal vibration

Figure 9

Significant compression

Figure 10

Strain elastography obtained by significant compression

Figure 11

No manual compression

Figure 12

Shear wave elastography obtained by no manual compression.

Figure 13

Tsukuba score (Elasticity score) (excerpted from article by Ito et al.)

Figure 14

Strain ratio (FLR: fat-to-lesion ratio)

Figure 15

A minimal breast cancer elastography image, a macroscopic image of the resected specimen, and an image of hematoxylin and eosin staining.

Figure 16a, b

RTE images of non-mass abnormalities around tumor (excerpted from article by Nakashima and Moriya). The presence or absence of intraductal tumor involvement is predicted using the elastography color patterns of the intraductal component.

Figure 17

Comparison of color changes in tumor and non-mass abnormality and pathological features (excerpted from article by Nakashima and Moriya). Color changes on elastography are useful for predicting the pathological features of intraductal progression.

Figure 18a, b

4D elastography and macroscopic findings of resected specimen. On 3D images, an isolated red band is depicted in a hard tumor depicted in blue. A soft region is suspected of being present in the superficial layer of the tumor, and the presence of intratumoral fat or necrotic cell debris is predicted. On the macroscopic image of the resected specimen, the yellow part in the upper center of the tumor corresponds to the same region.

Figure 19a, b, c

4D elastography and macroscopic image of resected specimen (tumor center and periphery). On 3D images, a hard region that is blue and linear is observed. A papillotubular carcinoma with wide spread intraductal components was detected in the pathological specimen.

Figure 20

Simple cyst. It is easy to diagnose with elastography.

Figure 21a, b

Complicated cyst (both top and bottom). It is difficult to recognize it as a cyst due to deformation, but it is estimated to be a cyst because the inside is liquid in nature.

Figure 22a, b, c

Fibroadenomas (a typical intracanalicular pattern, pericanalicular fibroadenoma)

Figure 23

Fibroadenoma (complex fibroadenoma)

Figure 24

Fat island. At first glance, it is visualized as an intramammary mass on B-mode images, but it can be assessed as intramammary fat on elastography as it presents as a strain image that is the same as that of adipose tissue.

Figure 25a, b

Mucinous carcinoma

Figure 26

Invasive ductal breast cancer (WHO: Invasive carcinoma, Nonspecific type¹⁵⁾). A tumor with internal calcification. Elastography demonstrates a relatively localized tumor.

Figure 27

Invasive ductal breast cancer (WHO: Invasive carcinoma, Nonspecific type¹⁵⁾). A tumor with suspected progression near the direction of breast ducts. Elastography, which depicts the progression as hard, demonstrates a tumor with an intraductal component.

Figure 28

Invasive lobular carcinoma. A mass that could be seen as an irregular hypoechoic area. On elastography, the center of the mass is depicted as blue, and the outline of the tumor is clear.

Figure 29

Ductal carcinoma in situ. An intramammary hypoechoic area and structural change are observed, and a blue neoplastic hard part is visualized on elastography, which are strongly suggestive of DCIS.

Figure 30

Ductal carcinoma in situ with calcification. A hypoechoic area with calcification. The areas with many tumor components are visualized as intense blue, and the areas with few tumor components are depicted as light blue.

Figure 31a, b

Color elastography (left) and gray-scale elastography (right) of invasive ductal breast cancer. a: The tumor is blue and clearly depicted. The elasticity score is 5. b: The tumor is filled with white, making it easy to measure the length of the hard area. The E/B ratio (see the 6-1-e) is calculated by comparing it with the length of the tumor in B-mode.

Figure 32

Strain ratio on color elastography. Select and calculate the stable part based on the graph. In this case, strain ratio and E/B ratio showed comparable values.

Figure 33a, b, c

Elastography image of papillotubular carcinoma, macroscopic image of resected specimen, and image of hematoxylin and eosin staining

Figure 34

An example of the time series analysis function for elasticity index (graph upper row) and elasticity ratio (lower row) after setting a reference target ROI (yellow) in the fat layer and three target ROIs (cyan, red, green) in the mass image.

Figure 35

The yellow arrow shows the level of the quality graph or quality bar, which is shown on the display and serves as a guide to compression status.

Figure 36a, b

B-mode, elastography, and macroscopic specimen images

Figure 37

Example workstation display (compression amplitude: 1.2 mm). It is possible to measure strain with an arbitrary shape.

Figure 38

Example workstation display (compression amplitude: 1.2 mm). It is possible to display the strain and the strain ratio of multiple locations together with the compression time phase.

Figure 39a, b, c

In invasive ductal carcinoma of 14 mm diameter large infiltration, adipose infiltration was found in a small part.

Figure 40

Fibroadenoma in a 40-year-old woman. Left: A well-circumscribed mass with homogeneous internal echoes and a small aspect ratio is observed.

Right: The mass is displayed as green in the color mode of eSie Touch™ elasticity imaging, indicating that the mass is softer than the surrounding tissue.

Figure 41

Invasive ductal breast cancer (papillotubular carcinoma) in a 47-year-old woman. Left: A mass with heterogeneous internal echoes and a large aspect ratio is observed. Right: The mass is displayed as red in the color mode of eSie Touch elasticity imaging, indicating that the mass is harder than the surrounding tissue.

Figure 42

Invasive ductal breast cancer (papillotubular carcinoma) in a 47-year-old woman. Left: The transverse diameter of the mass is 10.4 mm on a B-mode image. Right: The transverse diameter on a eSie Touch elasticity image is 13.6 mm, which is larger than that on the B-mode image.

Figure 43a, b

Invasive ductal breast cancer (papillotubular carcinoma) in a 47-year-old woman. Left: A mass is displayed as black on the VTI's gray-scale display, meaning that the mass is hard. The transverse diameter of the mass is 10.0 mm on a B-mode image. The transverse diameter on VTI is 13.4 mm, which is larger than that on the B-mode image. Right: The mass is displayed as red on the VTI color display, indicating that the mass is harder than the surrounding tissue.

Figure 44

Fibroadenoma in a 40-year-old woman. Vs in a hypoechoic mass is displayed as 1.26 m/sec using VTQ.

Figure 45a, b, c, d

Invasive ductal breast cancer (scirrhous cancer) in a 68-year-old woman. a: When the ROI is placed at the center of the mass using VTQ, Vs cannot be measured and X.XX is displayed. b: When the ROI is placed at the margin of the mass using VTQ, Vs is displayed as 5.42 m/sec. c: Macroscopic image. d: Image of hematoxylin and eosin staining

Figure 46a, b

Fibroadenoma in a 51-year-old woman. Left: Vs is displayed as 3.05 m/s using VTQ. Right: The tumor is displayed as green, i.e., soft, in VTIQ's velocity mode, and Vs is displayed as 3.13 m/s, 3.16 m/s, and 2.90 m/s. (Images provided by Dr. Atsuo Kawamoto, Tokyo Medical University Hospital)

Figure 47a, b, c

Invasive ductal breast cancer (papillotubular carcinoma) in a 68-year-old woman. Top left: Vs is displayed as X.XX, i.e., unmeasurable, using VTQ. Bottom left: A mass is displayed as red in VTIQ's velocity mode, meaning that the mass is hard. The internal Vs of the mass is 6.31 m/s. Right: A stable green level is guaranteed within the mass in VTIQ's quality mode. (Images provided by Dr. Atsuo Kawamoto, Tokyo Medical University Hospital)

Figure 48a, b, c

a) By continuously focusing the ultrasound beam on different depths within tissue, shear waves undergo coherent addition, forming a "mach cone" (yellow). As a result, shear waves are amplified and the propagation distance is extended. b) Shear wave generated by ultrasound beam. c) Shear wave propagated through a phantom containing a hard component (red circle). Shear wave propagation is fast through the red circle.

Figure 49

Four patterns of the visual evaluation

Figure 50

Small invasive cancer coded blue homogeneously (Blue cancer)

Figure 51a, b

ShearWave™ Elastography (SWE) images. A (B-mode image): A hypoechoic mass with a rough margin and a large aspect ratio is observed outside the left breast. B (SWE image): Quantitative values can be measured by using Q-Box™ at an arbitrary site. Elasticity has been measured at the tumor margin (1), interior of tumor (2, 3), and normal mammary gland (4), and the quantitative value for each is displayed at the right.

Figure 52

The lesion is a cyst, but it appears to be a lesion with high tissue elasticity when compression is applied (from reference 42). The arrows indicate ribs. Take note of the structure of the deep region when performing examinations.

Figure 53a, b

ShearWave elastography image of fibroadenoma and image of hematoxylin and eosin staining

Figure 54a, b, c

ShearWave elastography image of phyllodes tumor, image of resected specimen cross section, and image of hematoxylin and eosin staining

Figure 55a, b, c

ShearWave elastography image of the invasive ductal breast cancer, image of the resected specimen cross section, and the image of hematoxylin and eosin staining

Table 1. Elastography Classification (Except Mechanical Vibration Type)

Elastography Classification (Except Mechanical Vibration Type)

	Strain or Displacement (Strain Imaging)			Shear Wave Speed (Shear Wave Imaging)		
Manual Compression	Strain elastography					
	No Compression	Elastography	<i>Philips</i>			
		eSie Touch™ Elasticity Imaging	<i>Siemens</i>			
	Minimal Vibration	Real-time Tissue Elastography (RTE)	<i>Hitachi</i> <i>Aloka</i>			
		Elastography	<i>GE</i>			
	Significant Compression	Real-time Tissue Elastography (RTE)	<i>Hitachi</i> <i>Aloka</i>			
		Elastography	<i>GE</i>			
		Elastography	<i>Toshiba</i>			
	Acoustic Radiation Force Impulse	Acoustic Radiation Force Impulse (ARFI) Imaging				Point shear wave elastography (average shear wave speed) ^t
Virtual Touch™ Imaging (VTI)		<i>Siemens</i>	Virtual Touch™ Quantification (VTQ)		<i>Siemens</i>	
			Shear wave elastography (average shear wave speed)			
			ShearWave Elastography (SWE)		<i>SSI</i>	
			Virtual Touch™ IQ (VTIQ)		<i>Siemens</i>	

Hitachi Aloka = Hitachi Aloka Medical, *GE*=GE Healthcare, *Philips*=Philips Healthcare, *Toshiba*=Toshiba Medical, *SSI*=SuperSonic Imagine

Fig.1

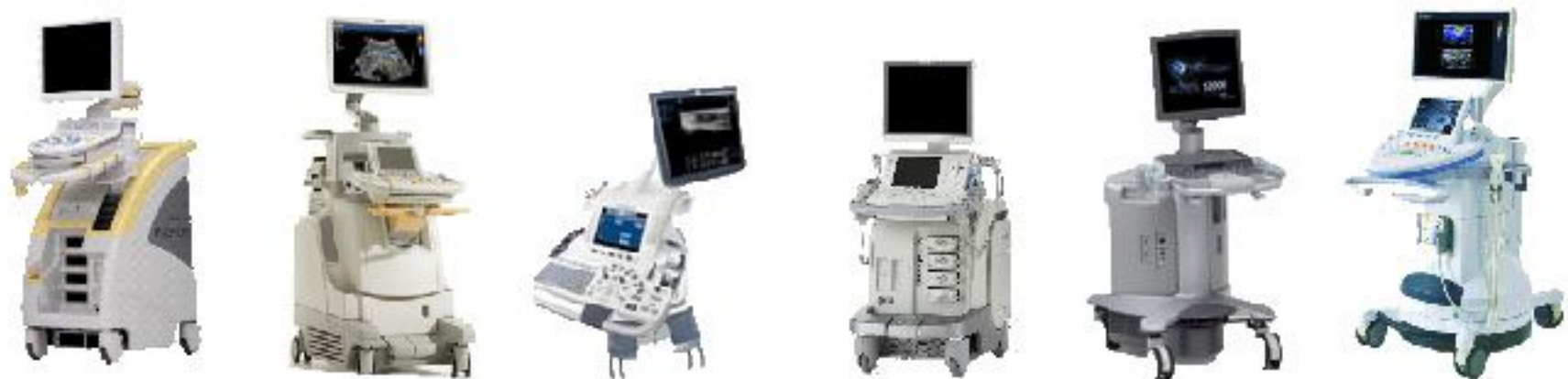

Fig.2

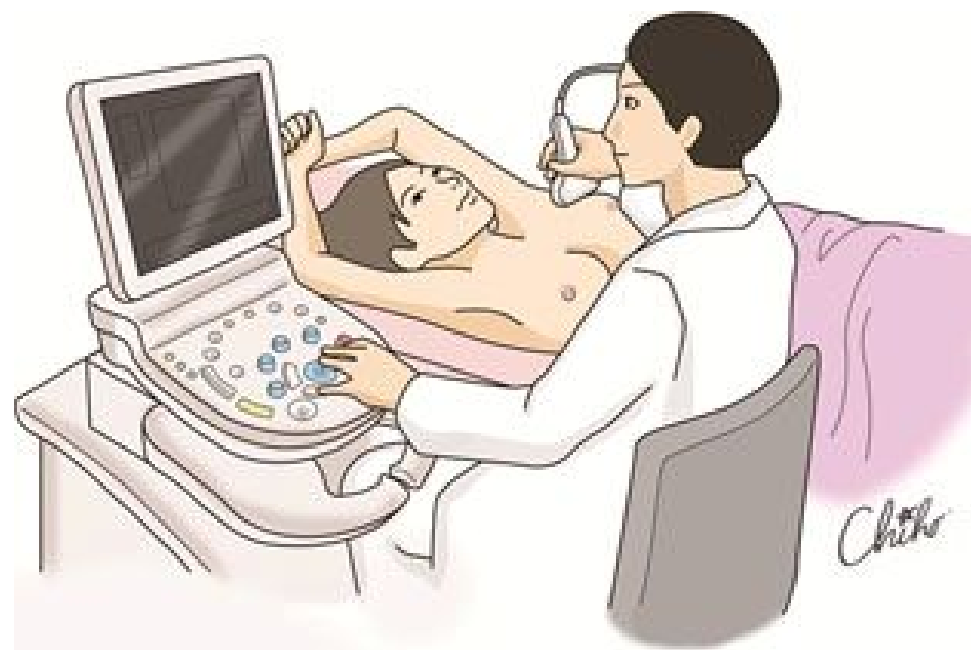


Fig.3

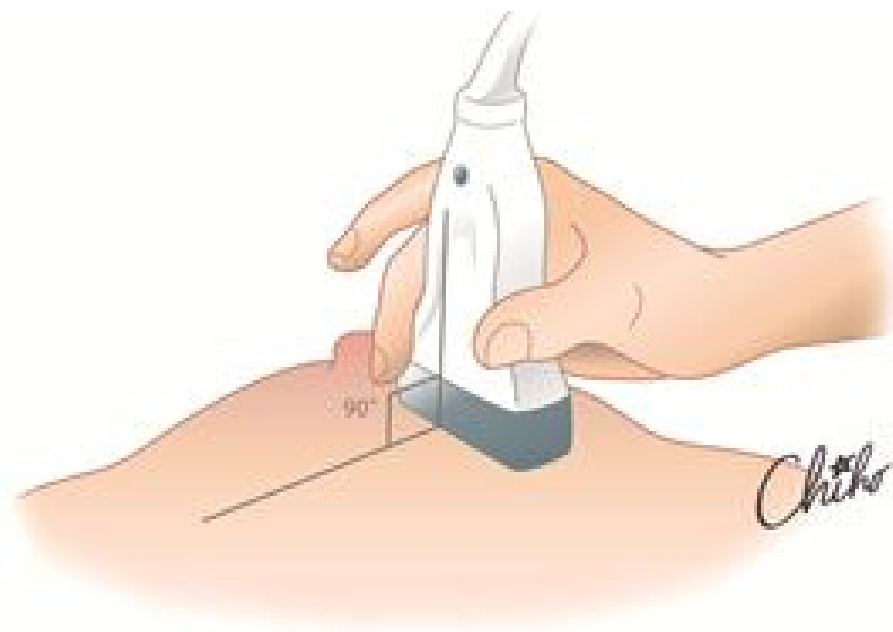


Fig.4

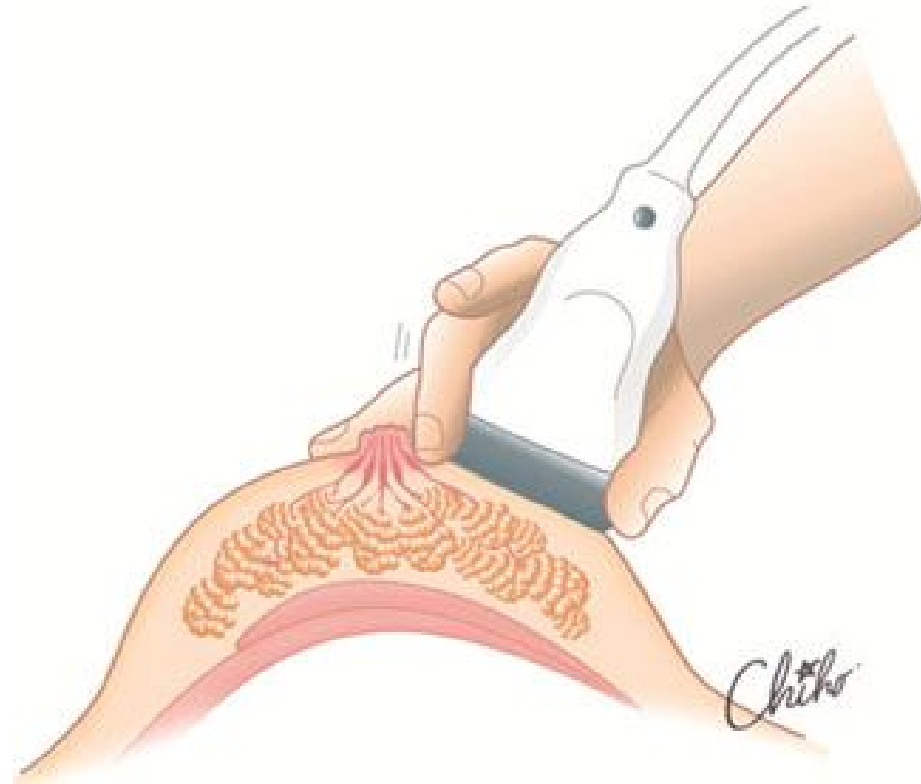

Fig.5

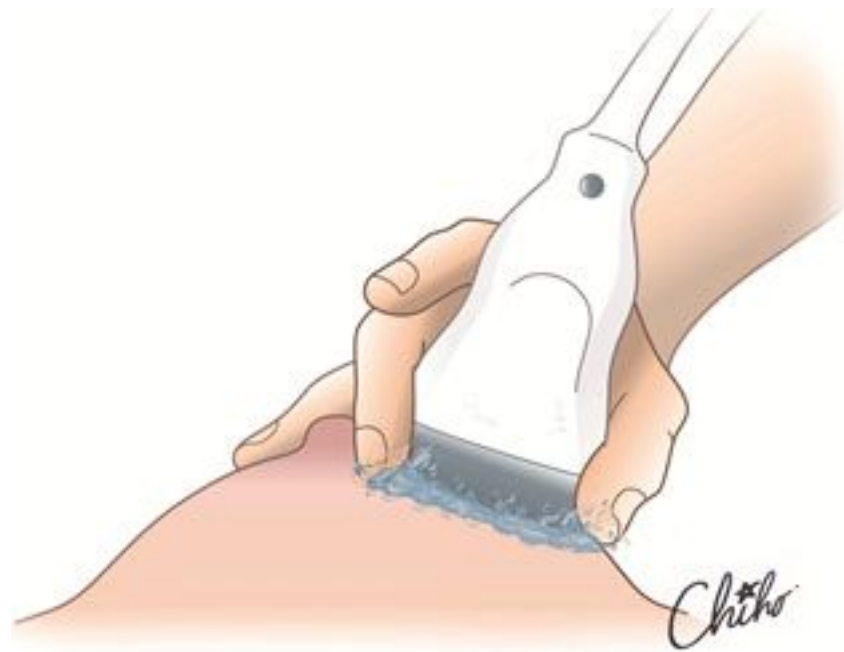

Fig.6

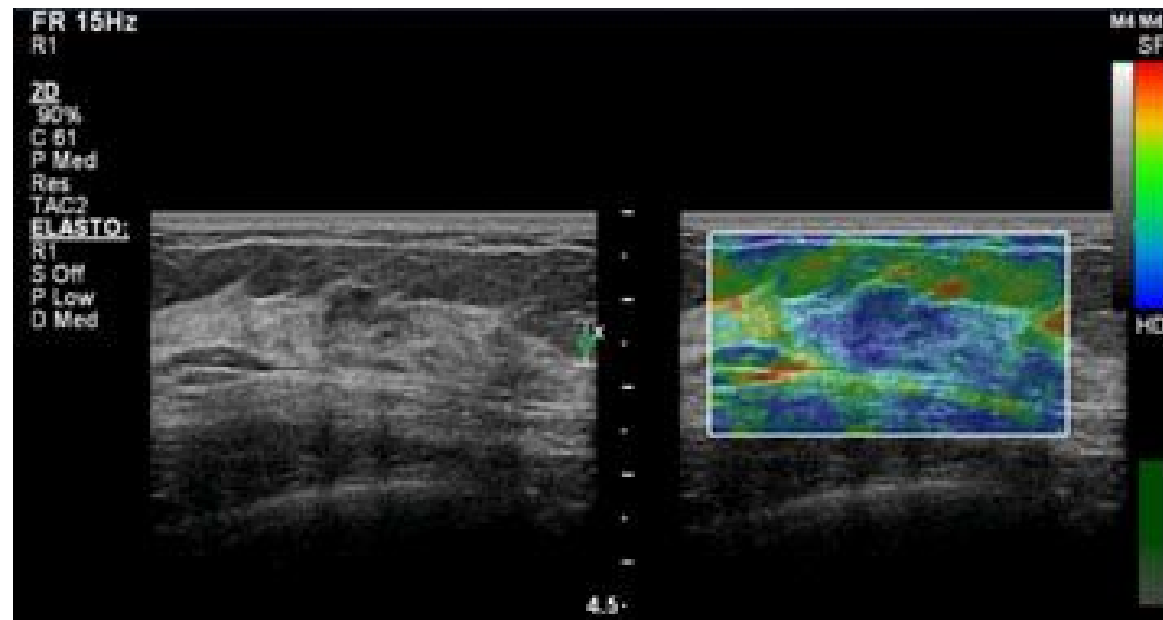


Fig.7

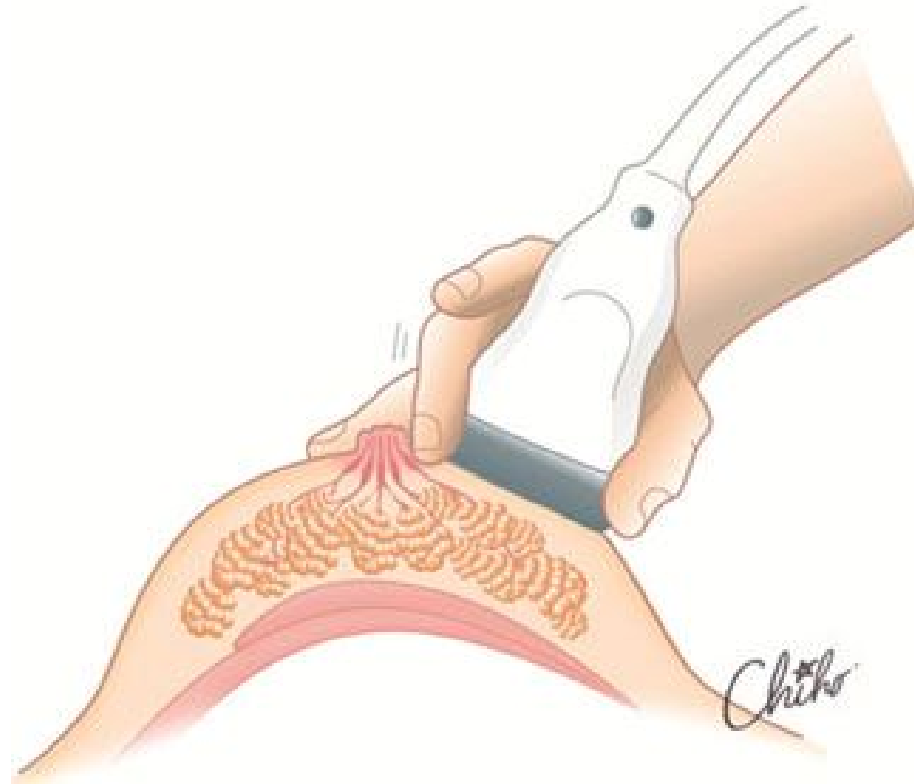

Fig.8

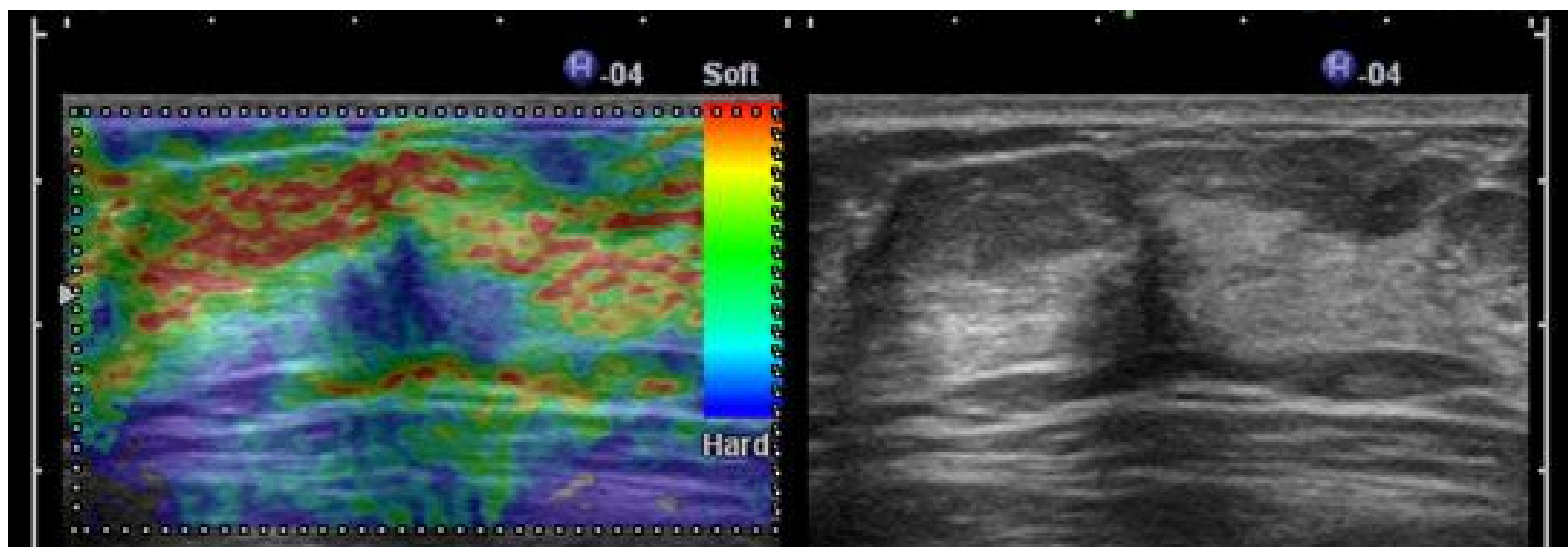


Fig.9

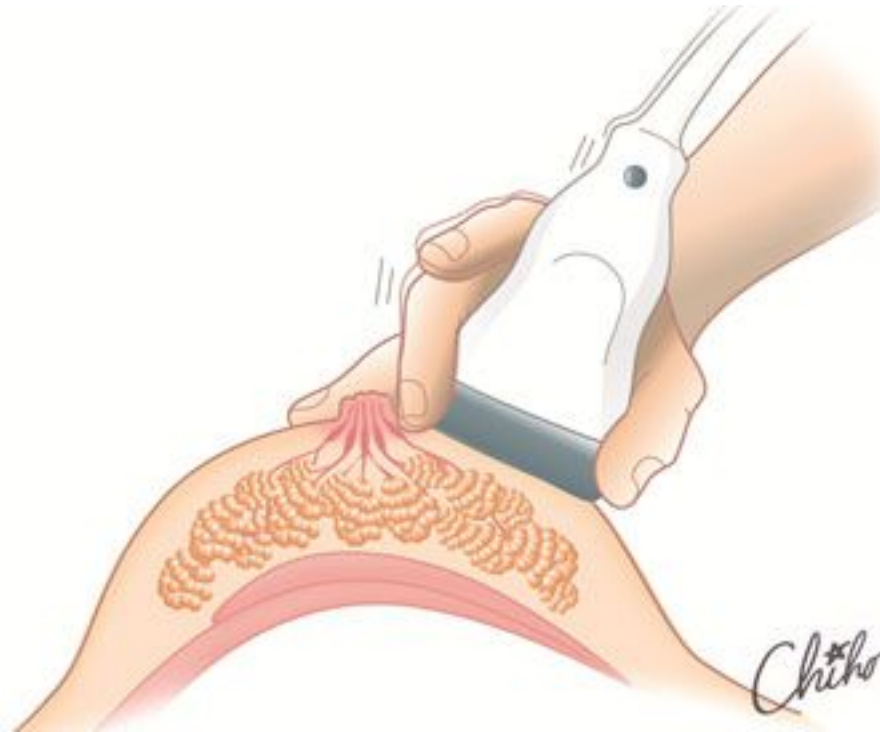


Fig.10

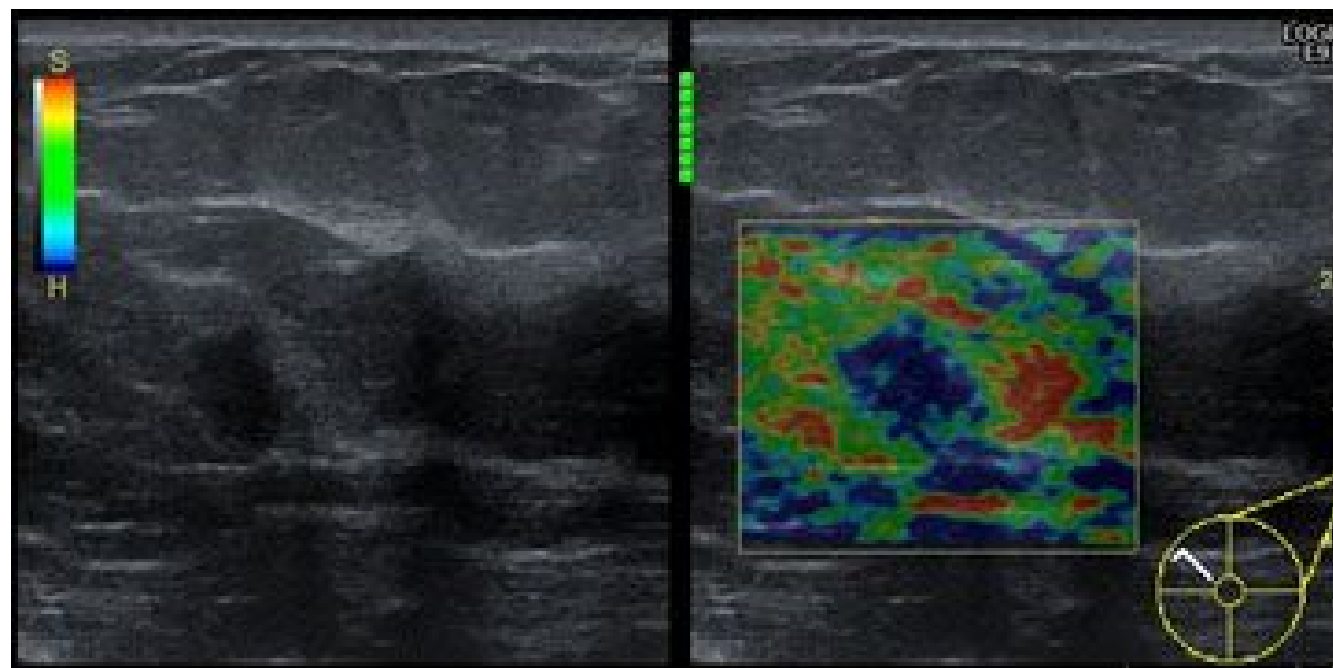


Fig.11

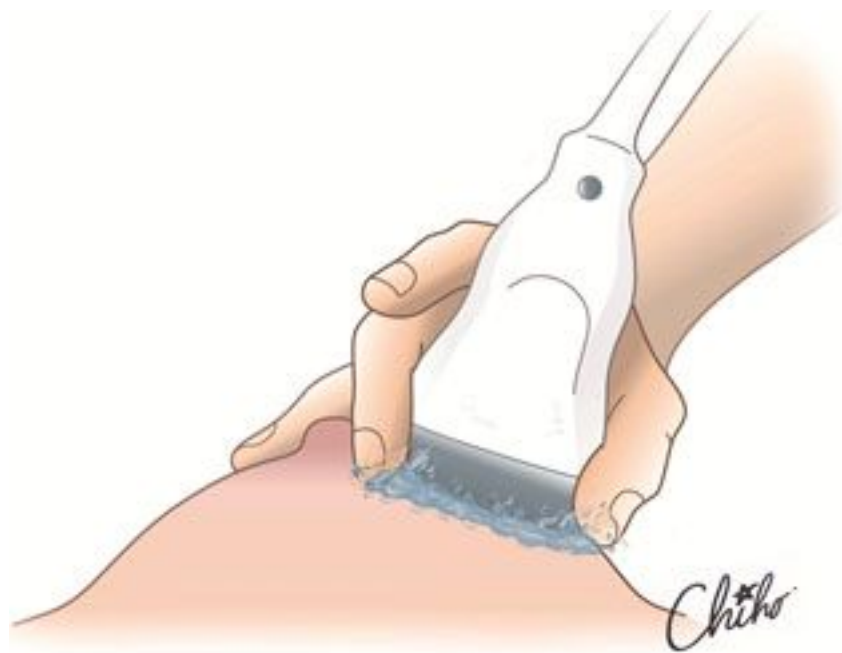

Fig.12

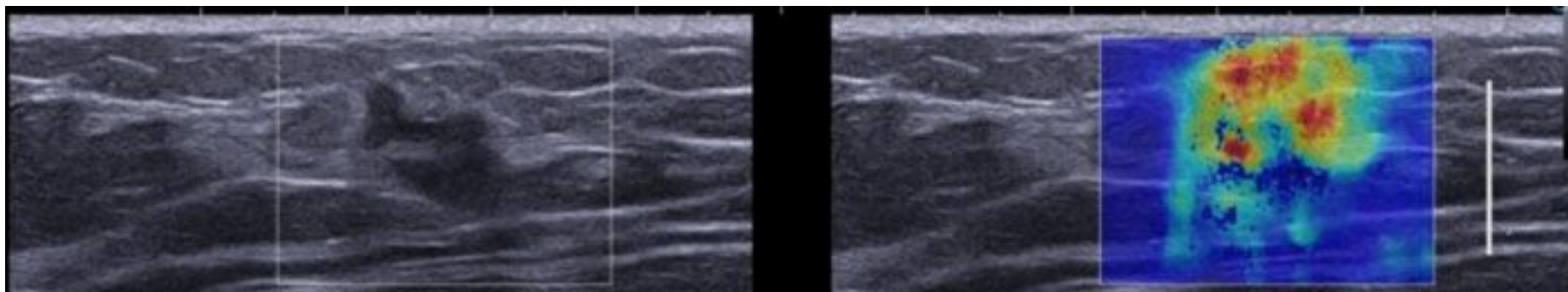


Fig.13

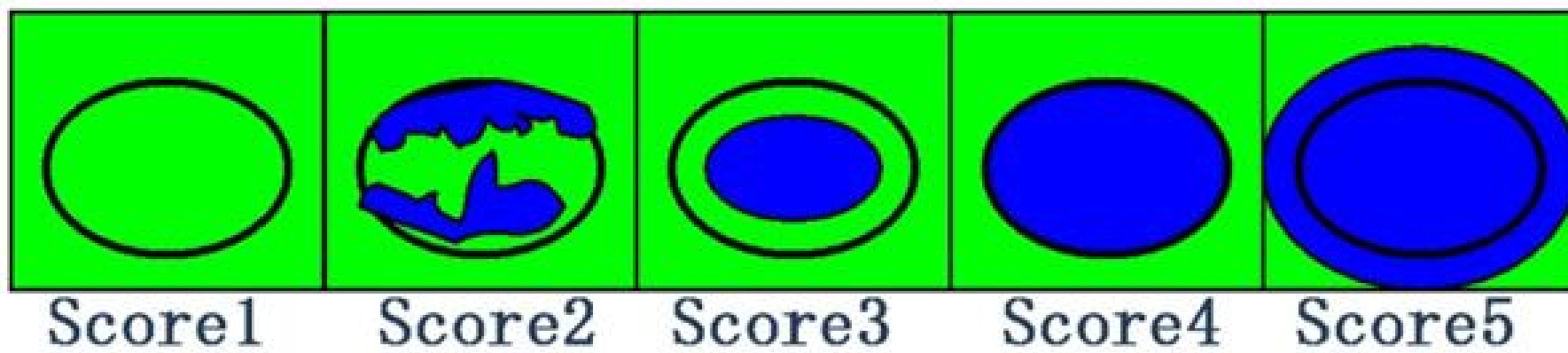


Fig.14

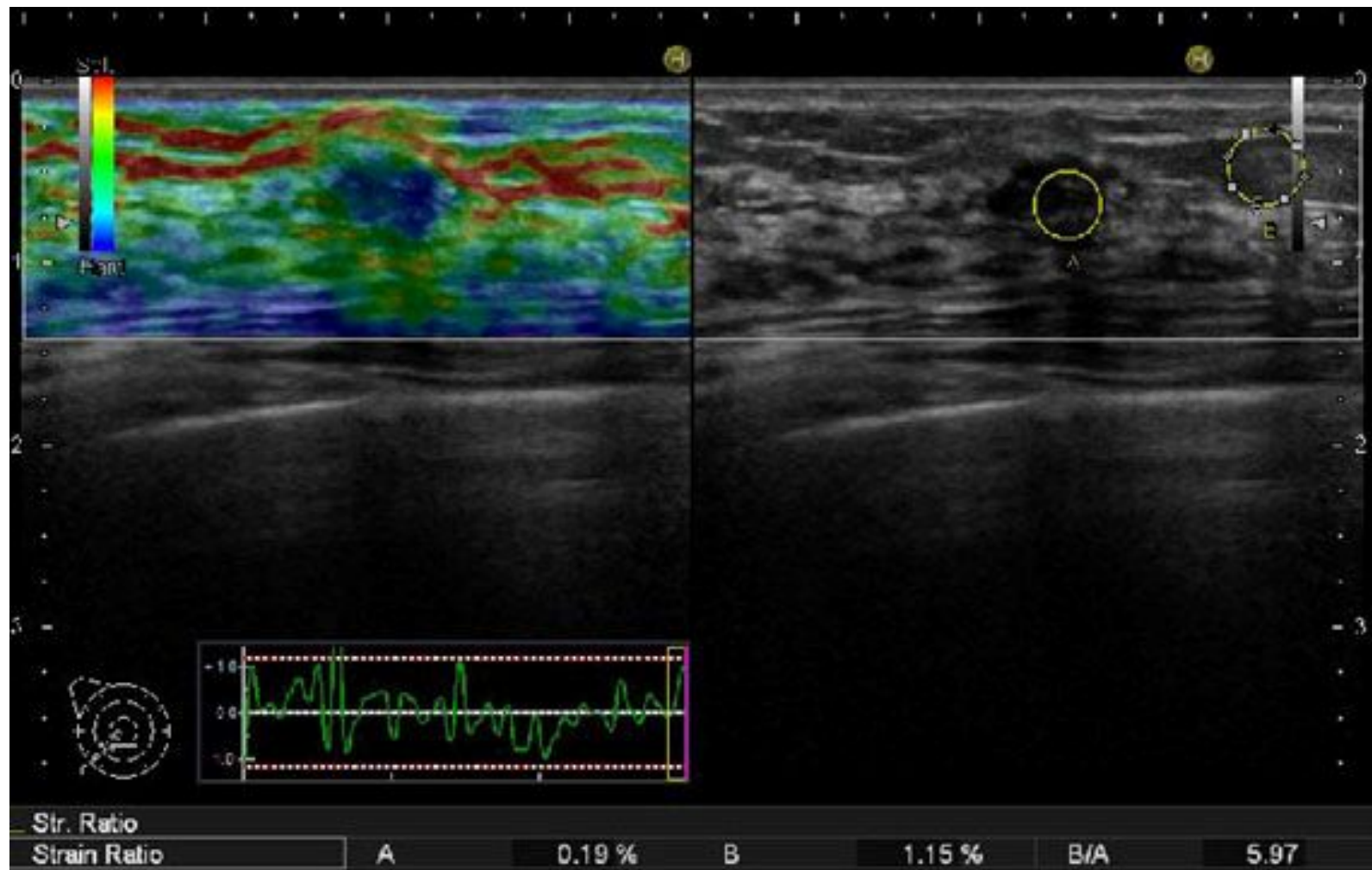


Fig.15

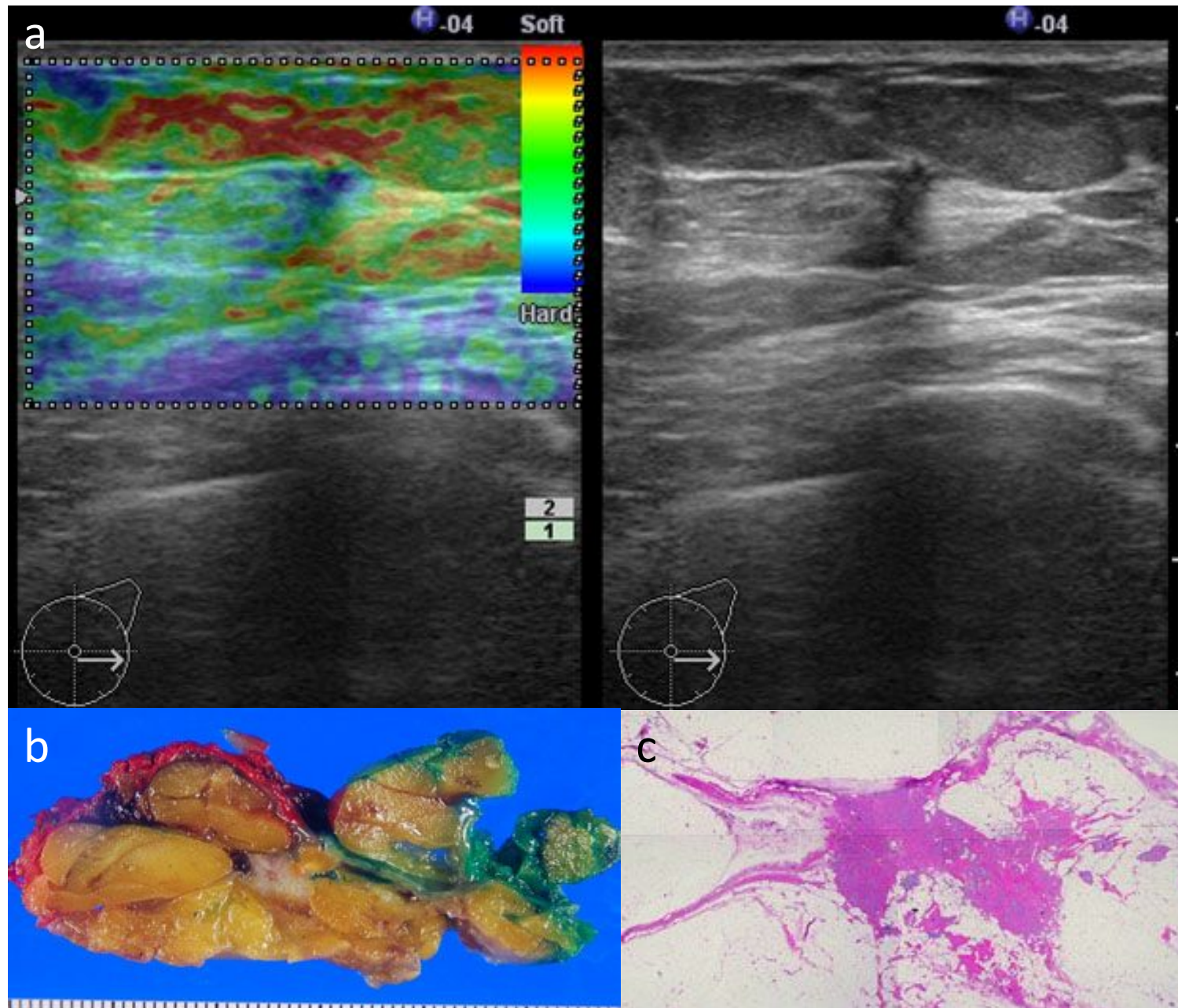


Fig.16

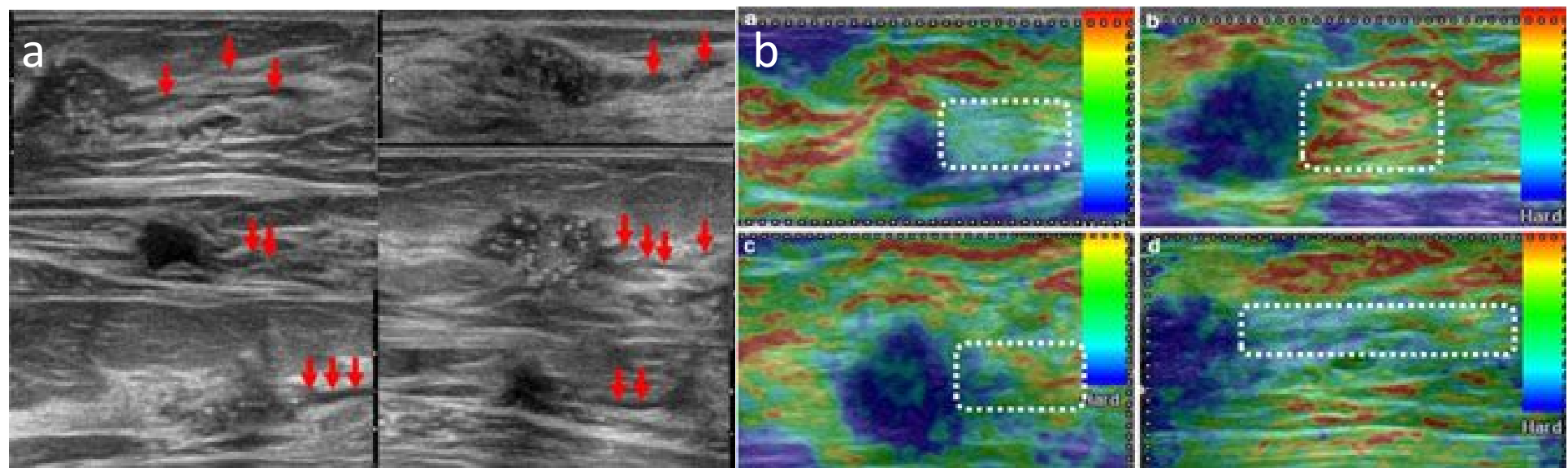
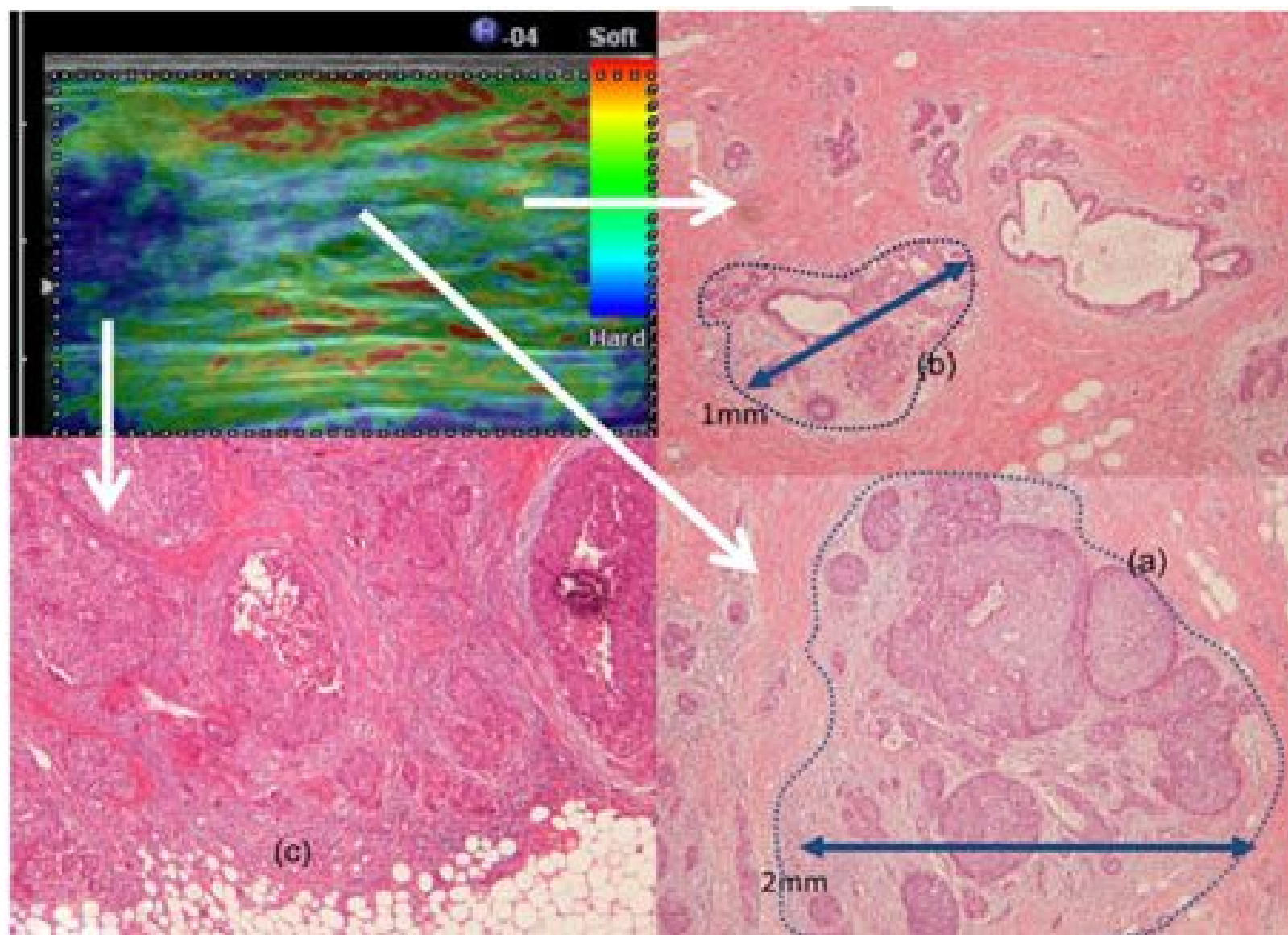


Fig.17



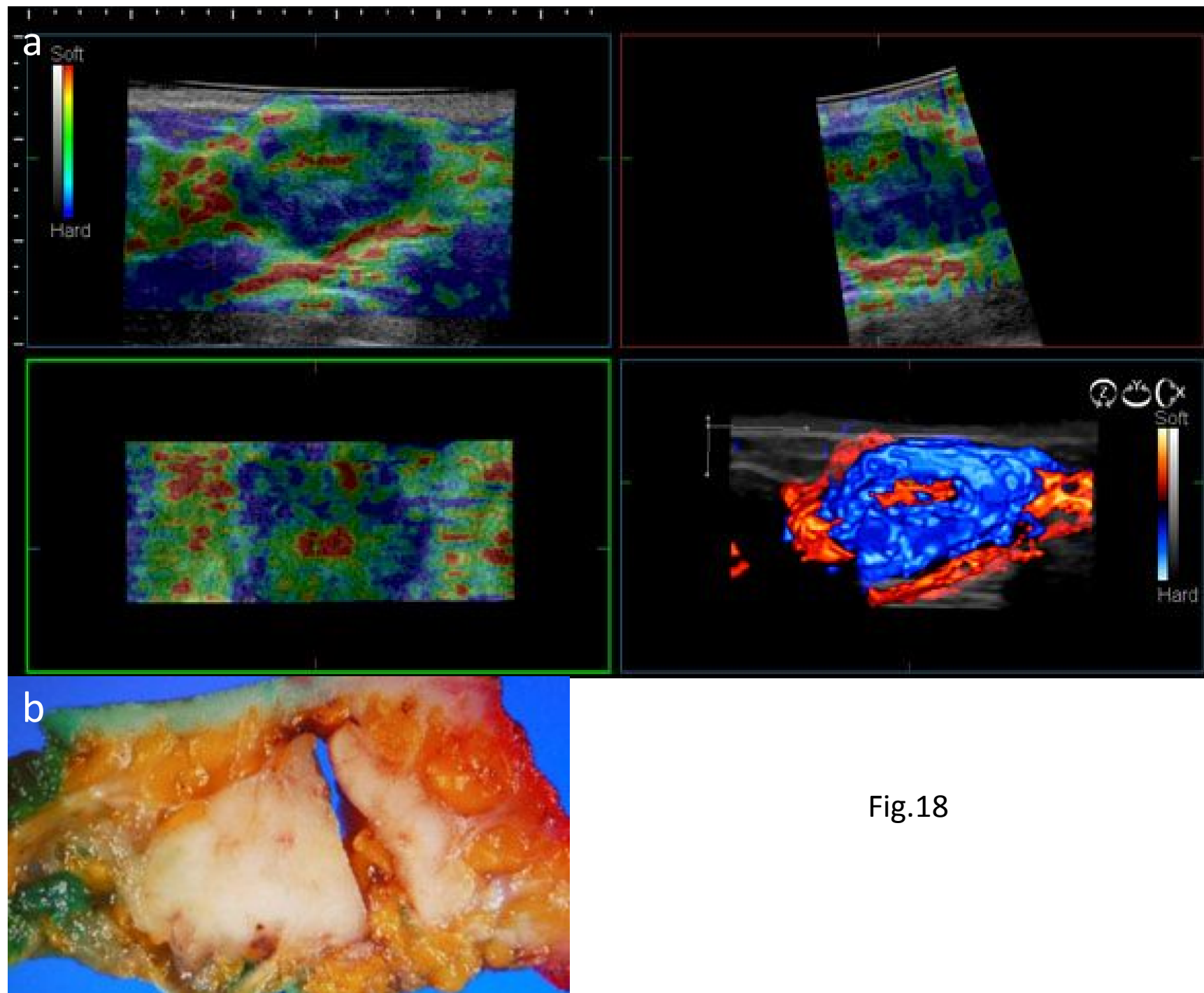


Fig.18

Fig.19

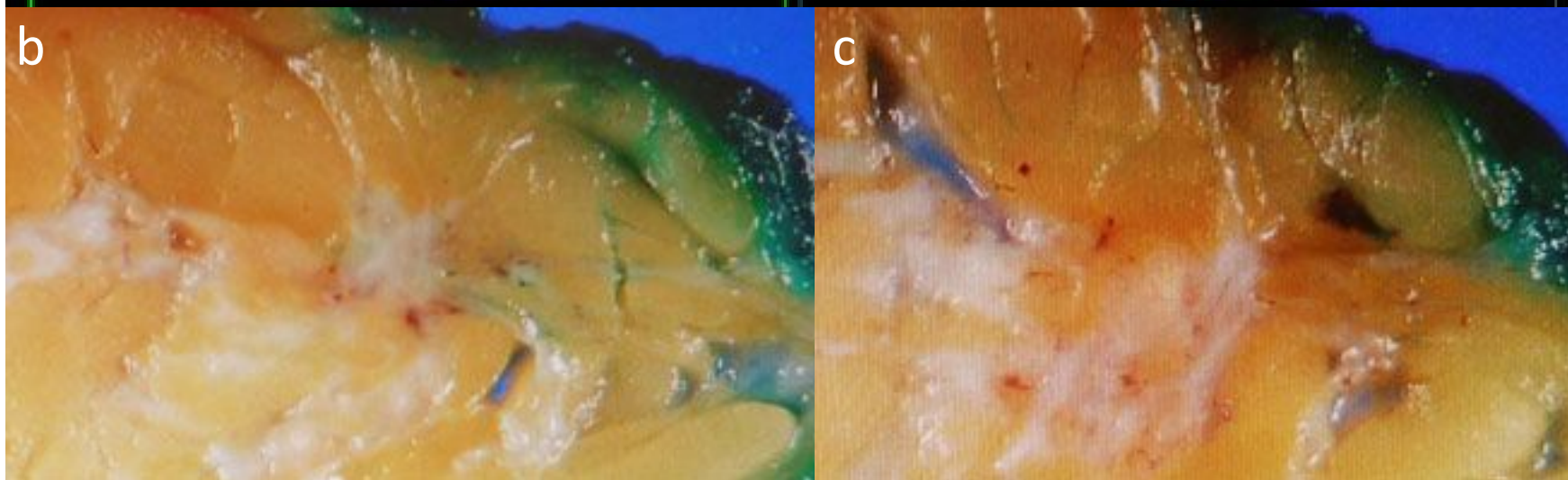
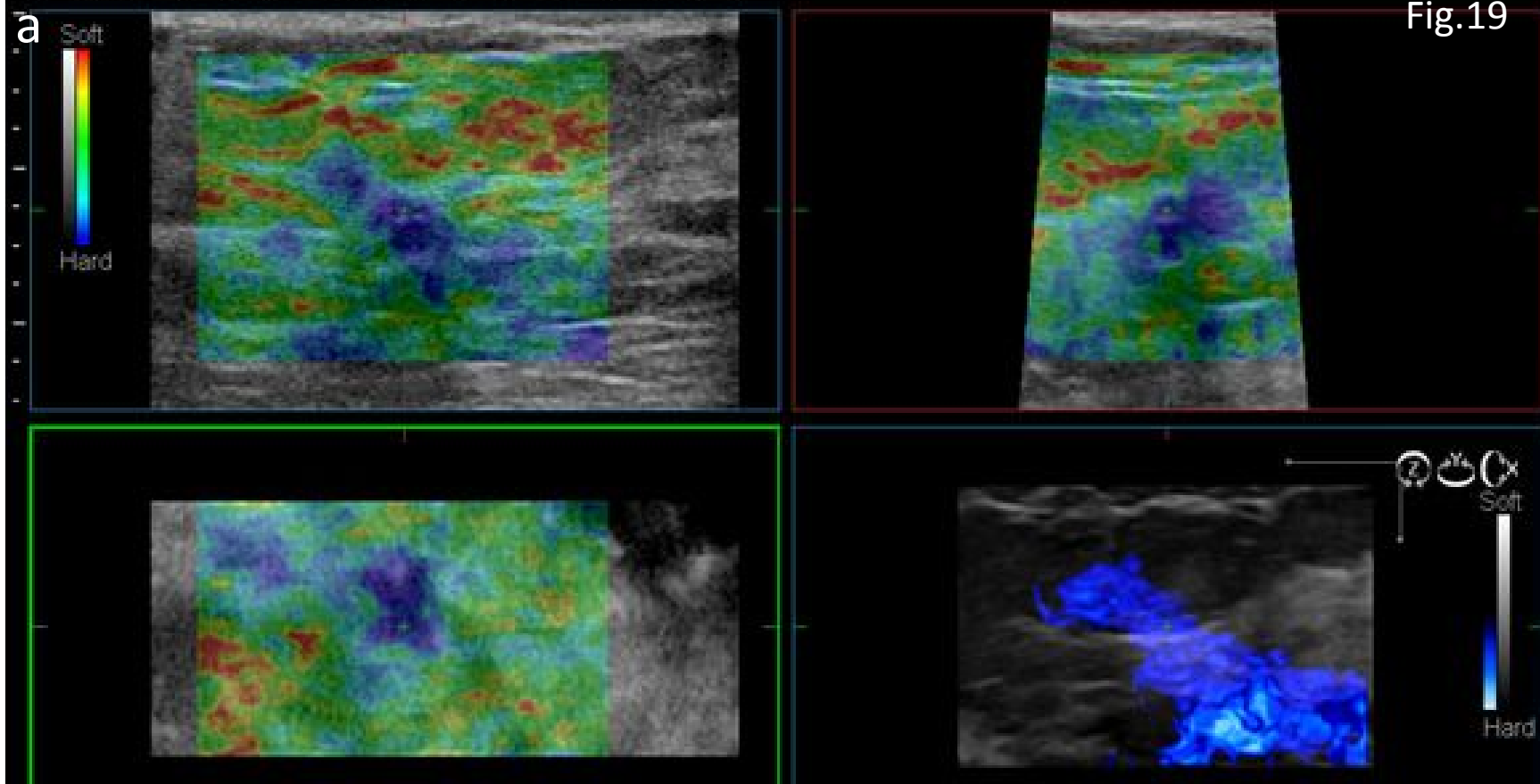
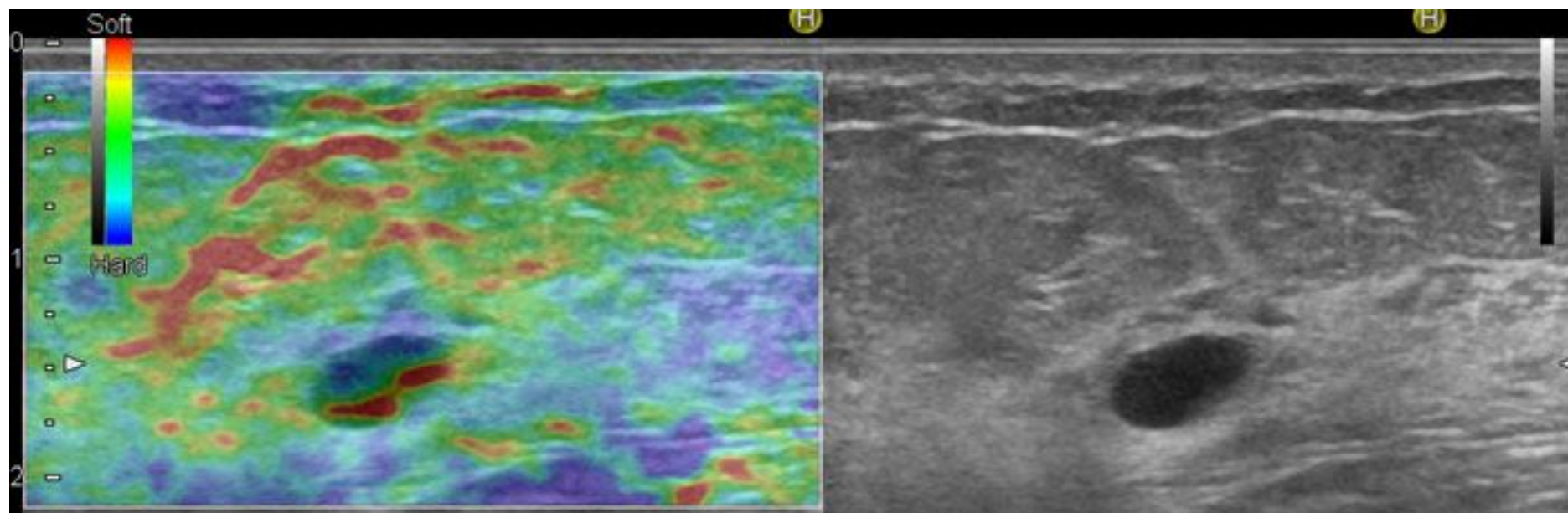


Fig.20



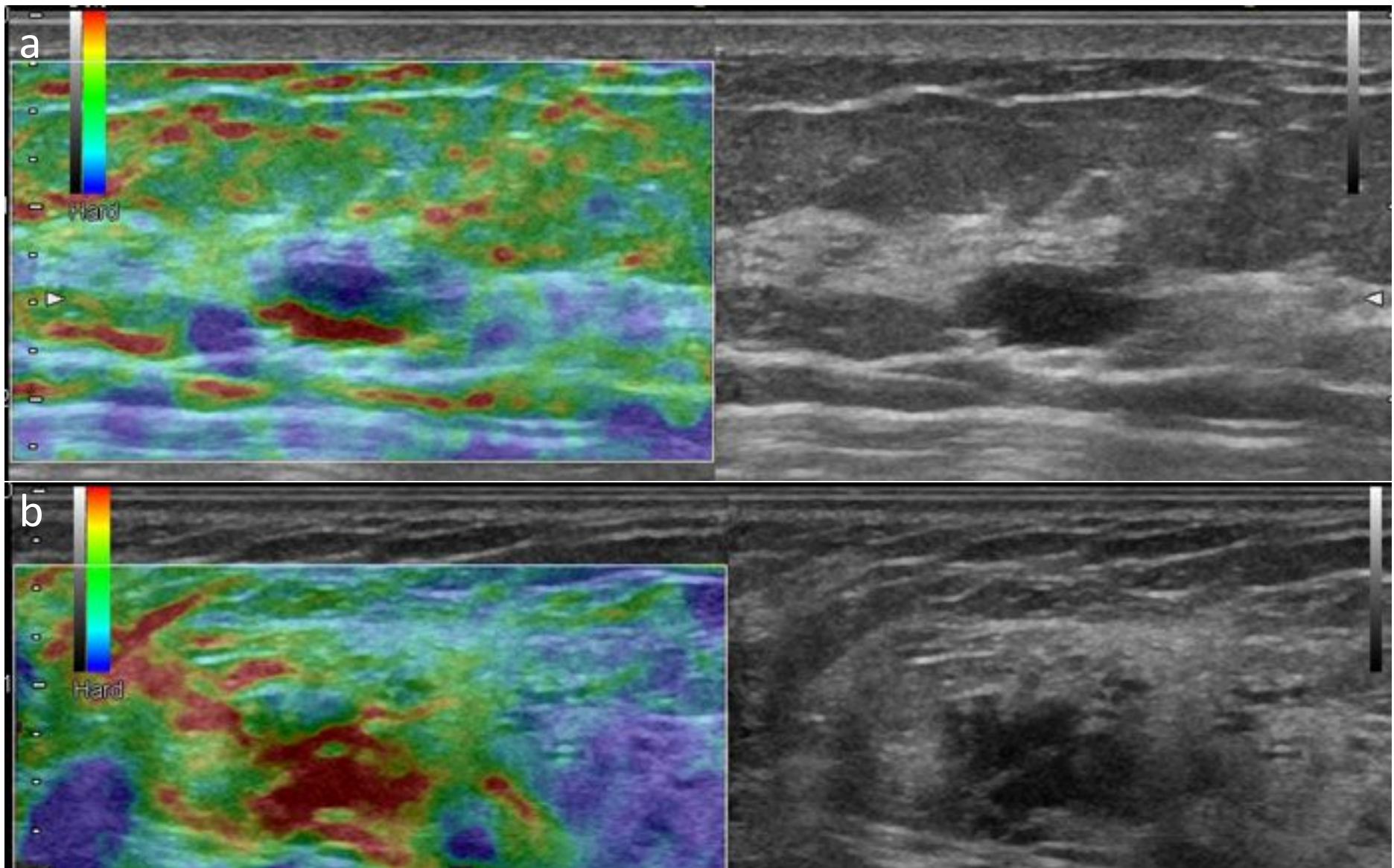


Fig.21

Fig.22

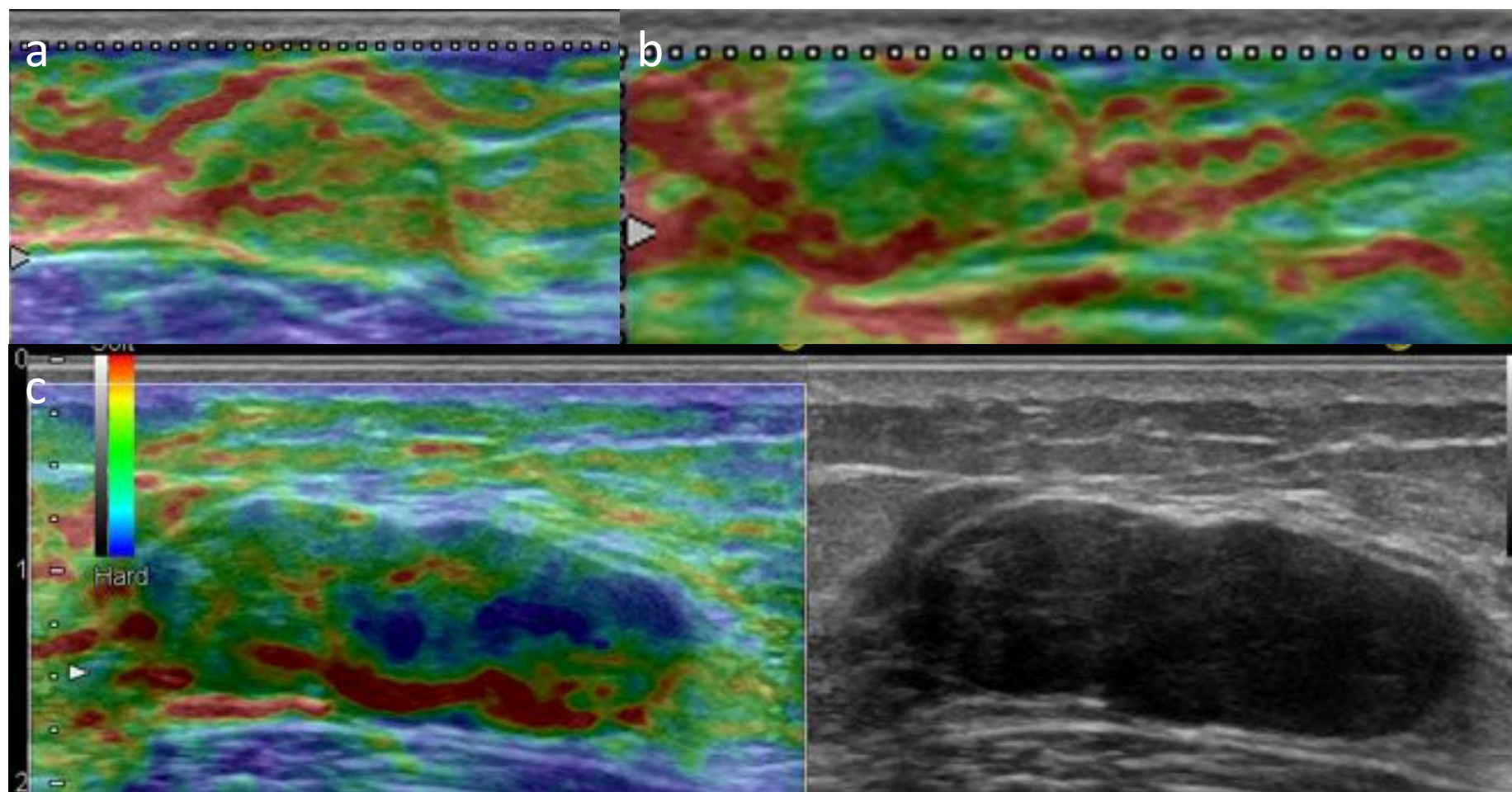


Fig.23

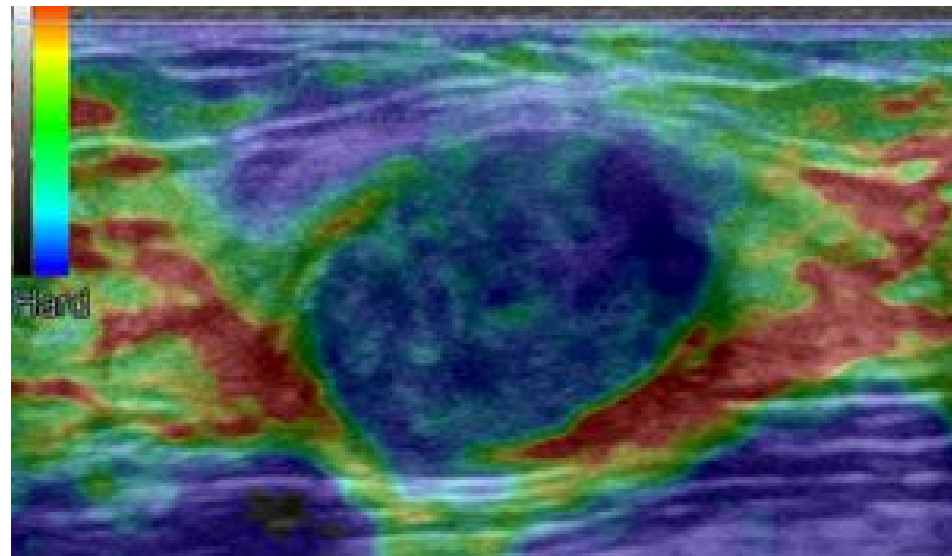


Fig.24

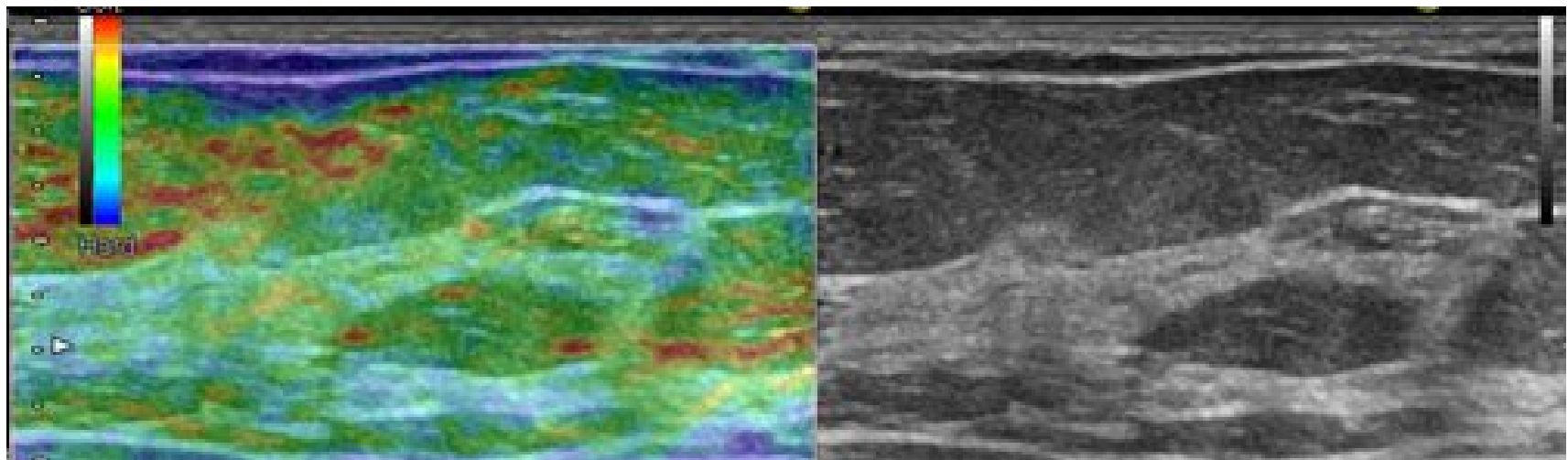


Fig.25

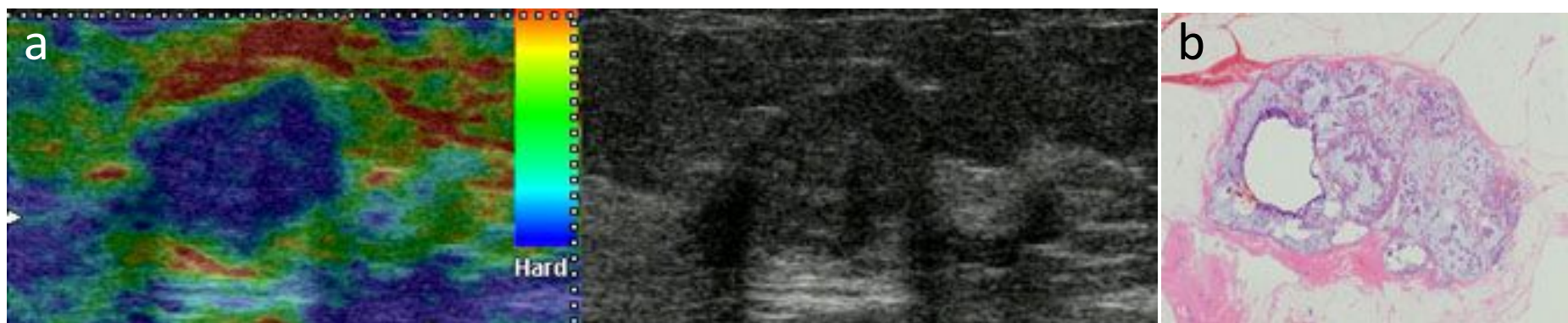

Fig.26

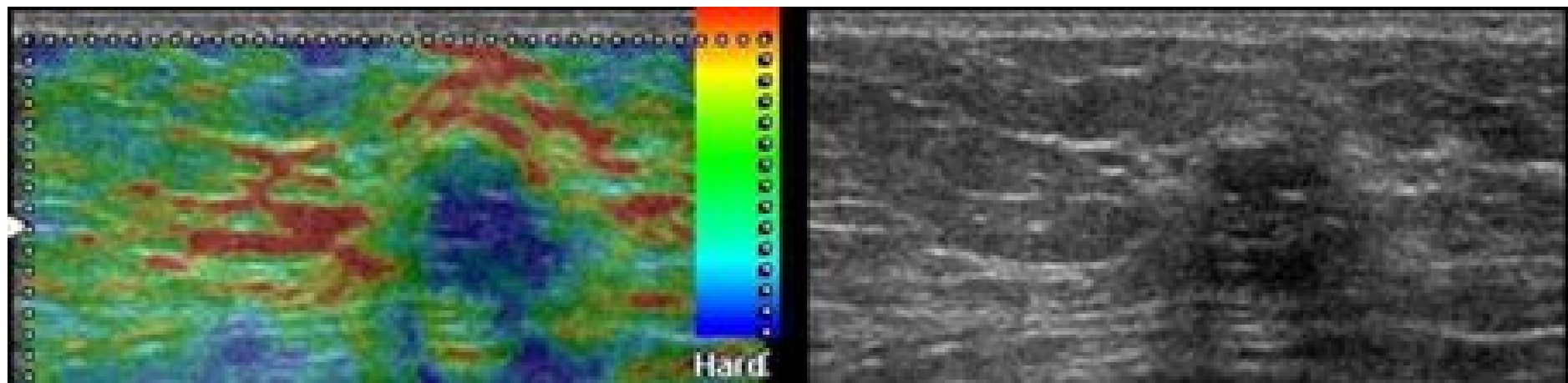


Fig.27

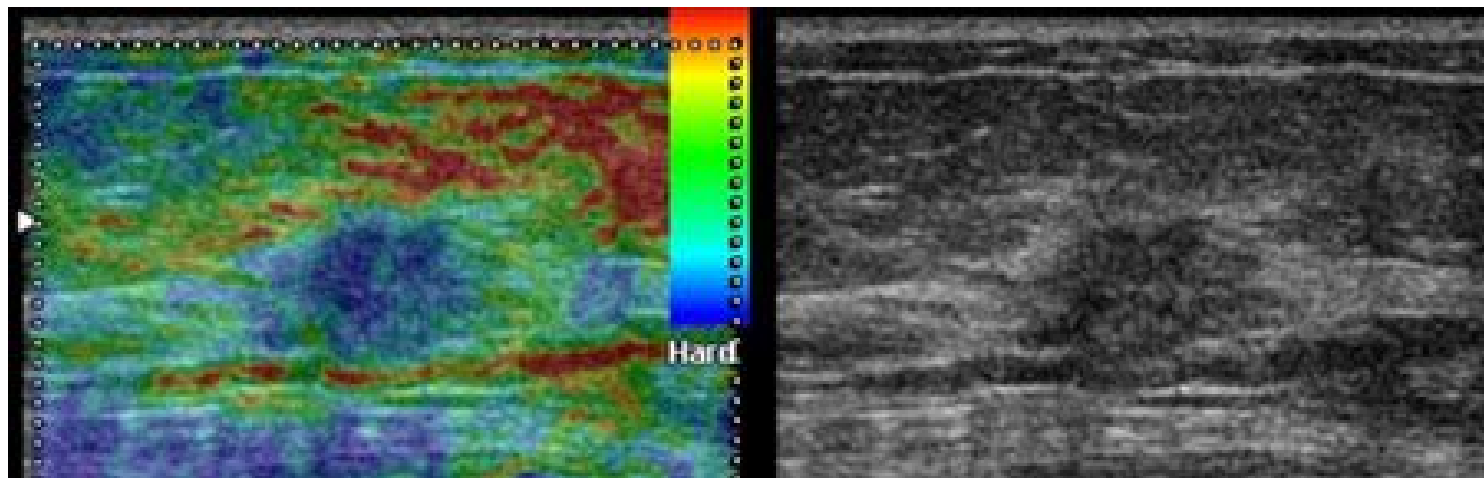


Fig.28

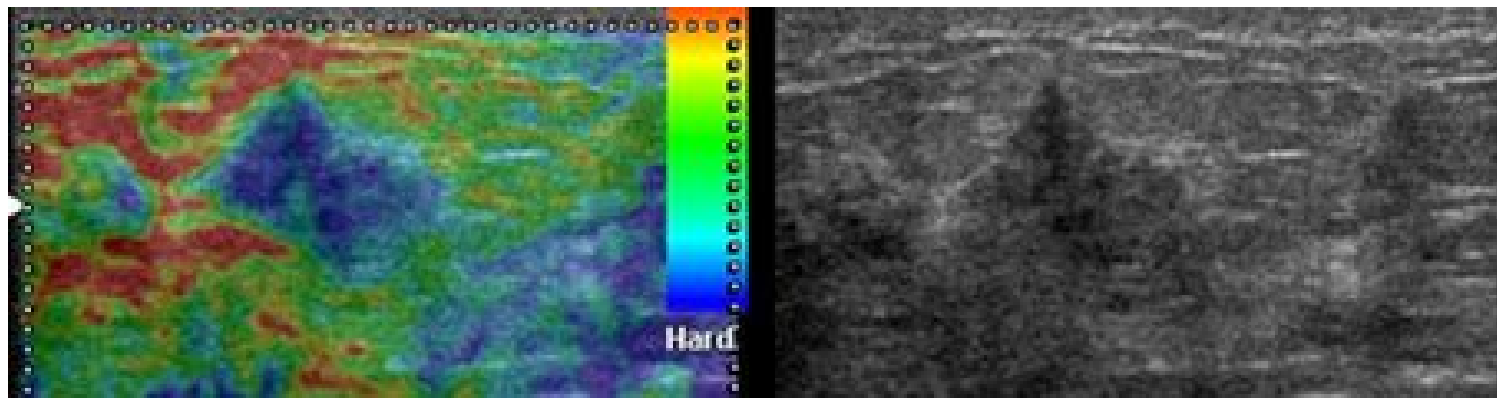


Fig.29

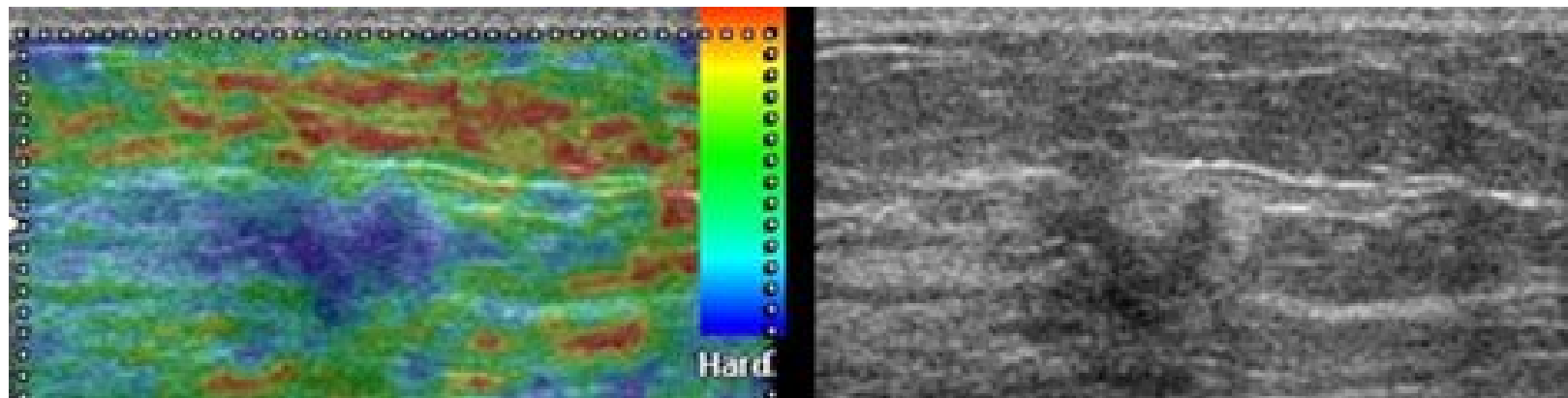


Fig.30

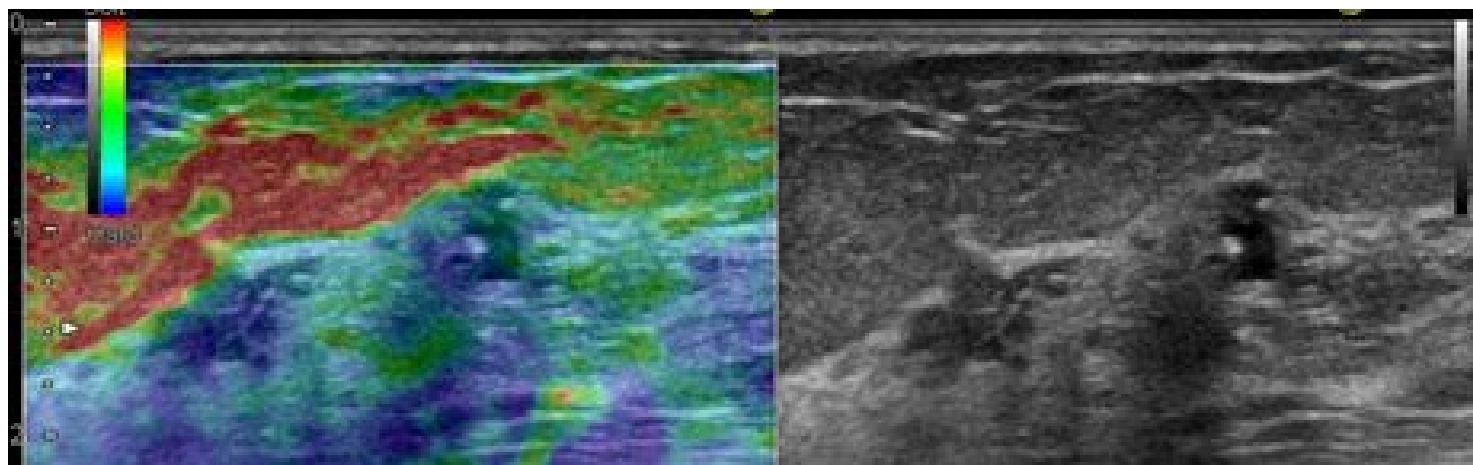


Fig.31

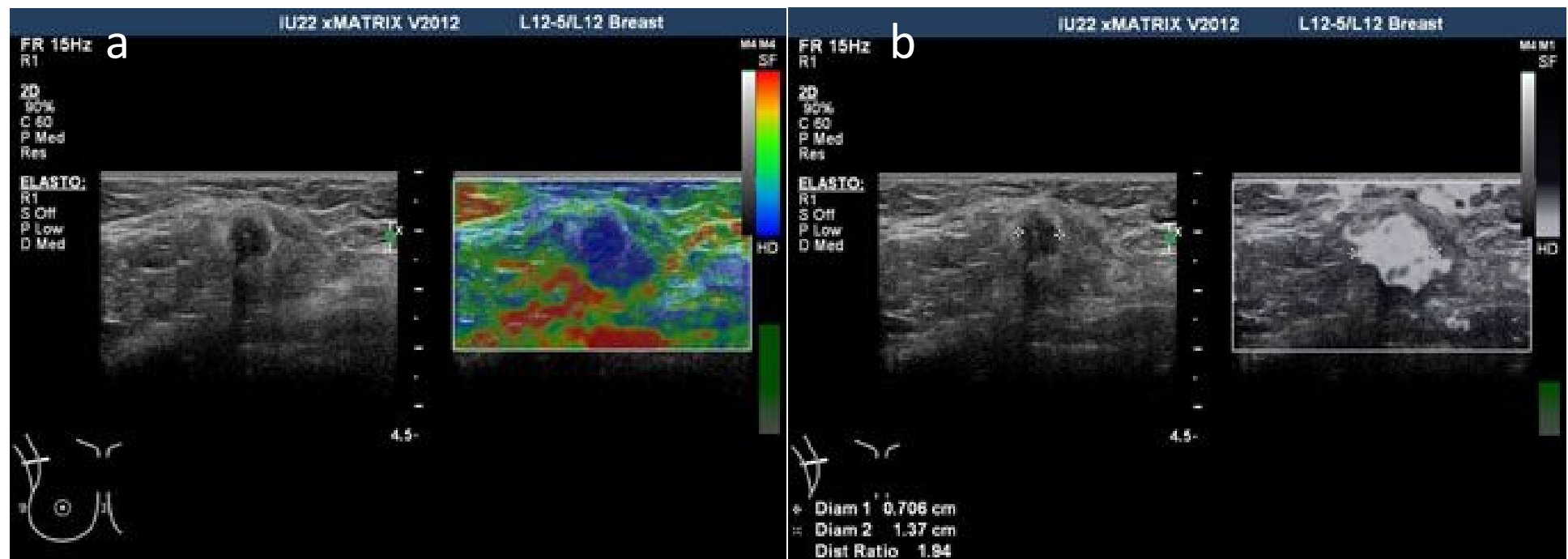


Fig.32

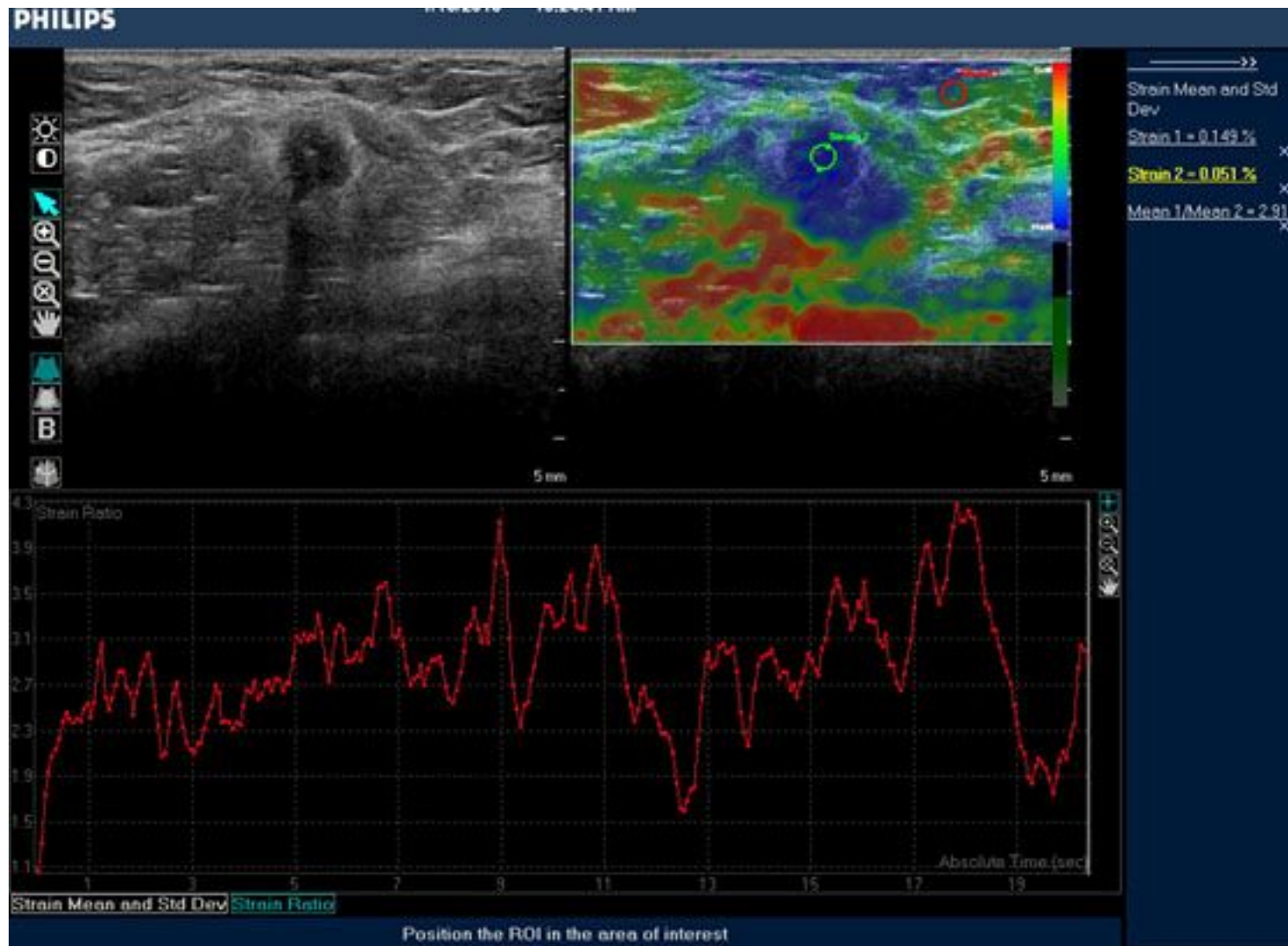


Fig.33

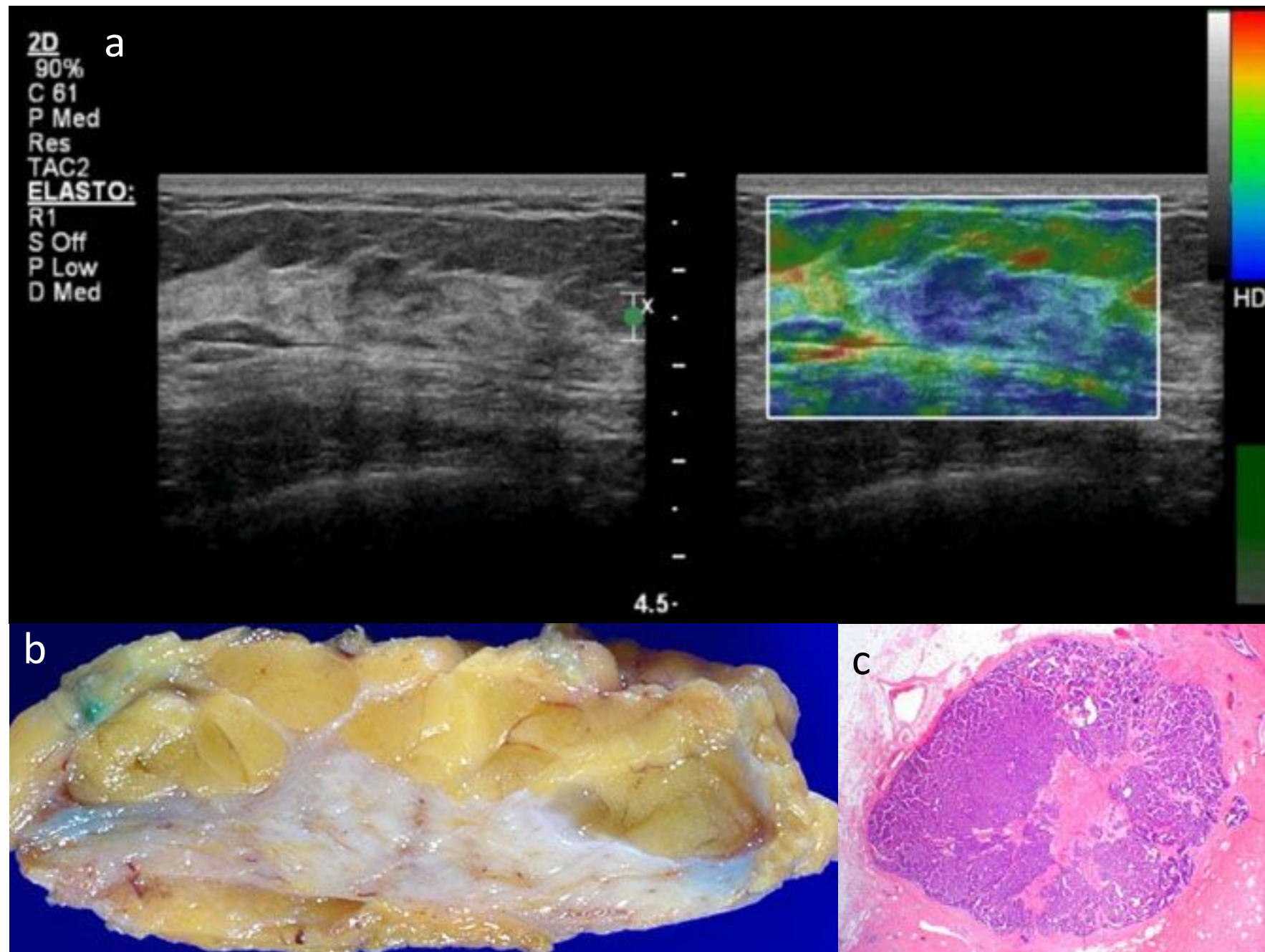


Fig.34

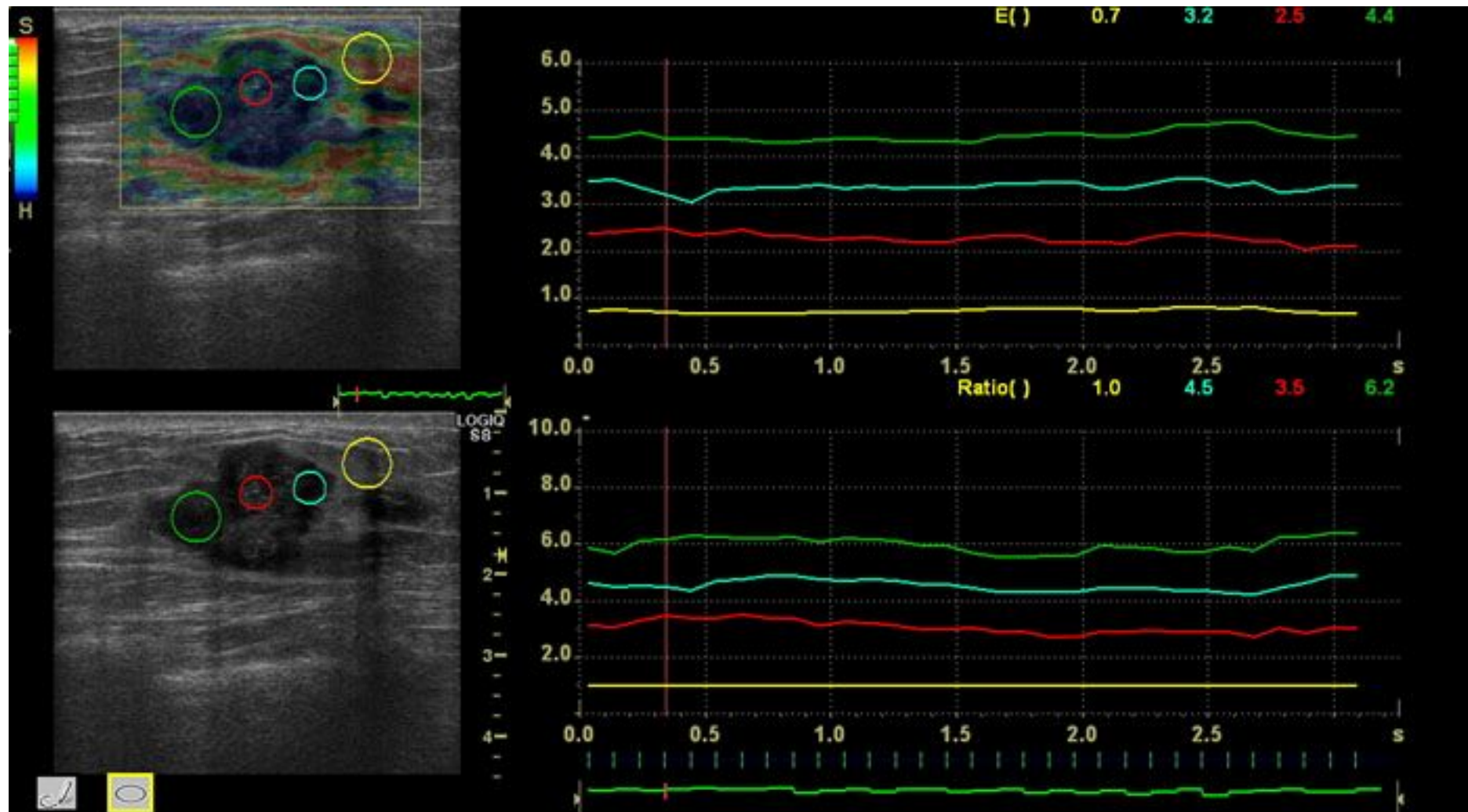


Fig.35

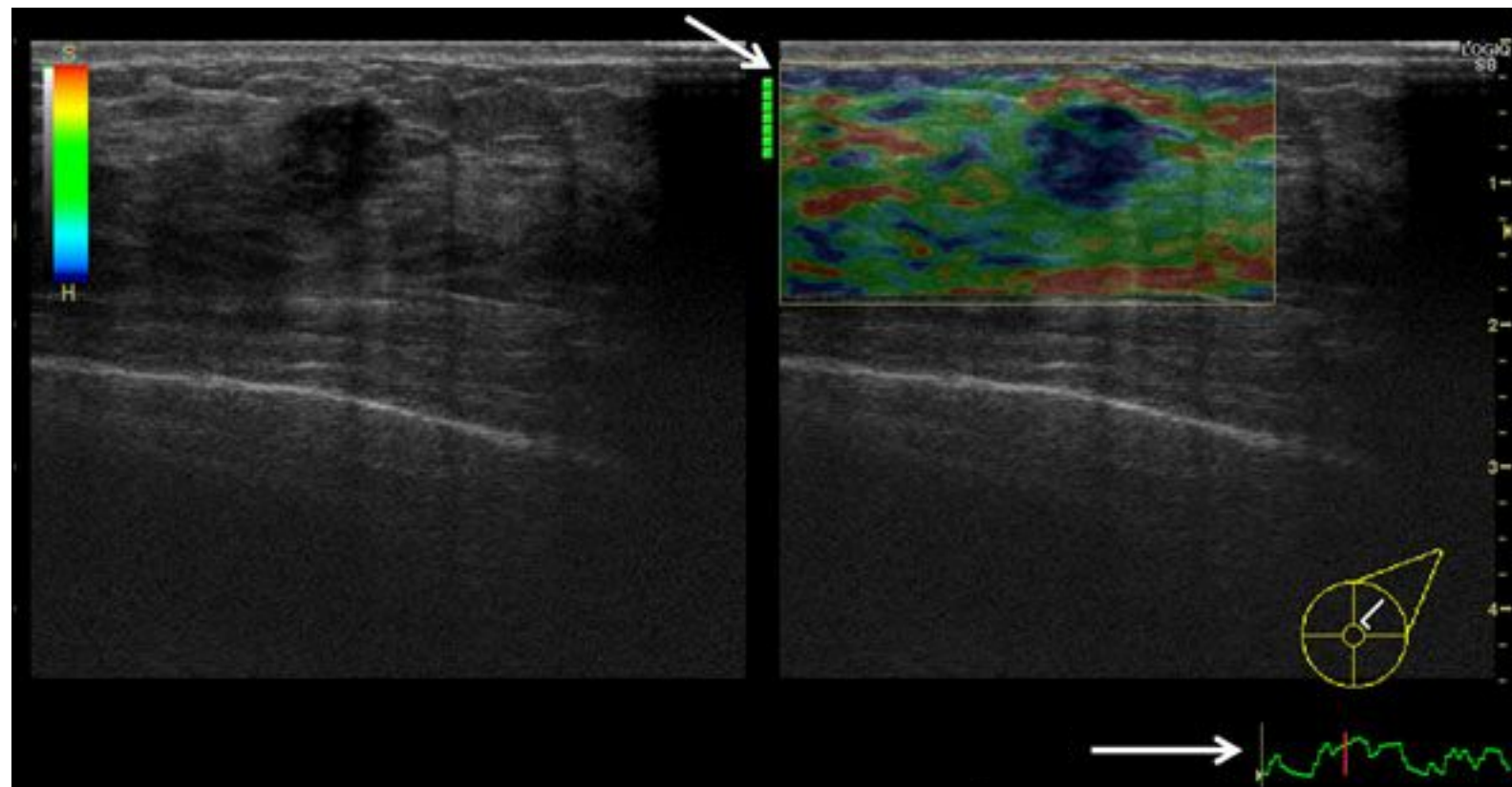


Fig.36

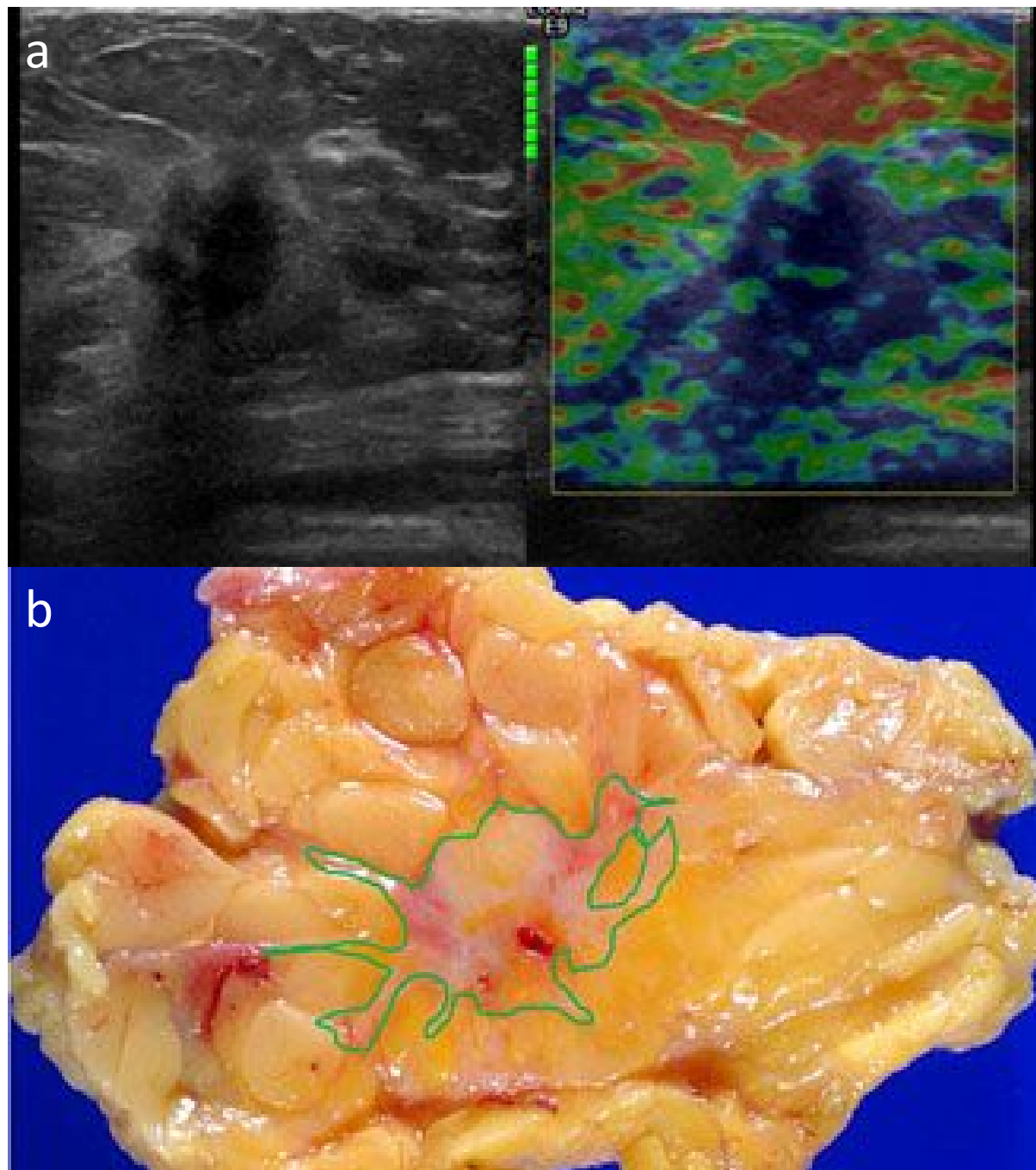


Fig.37

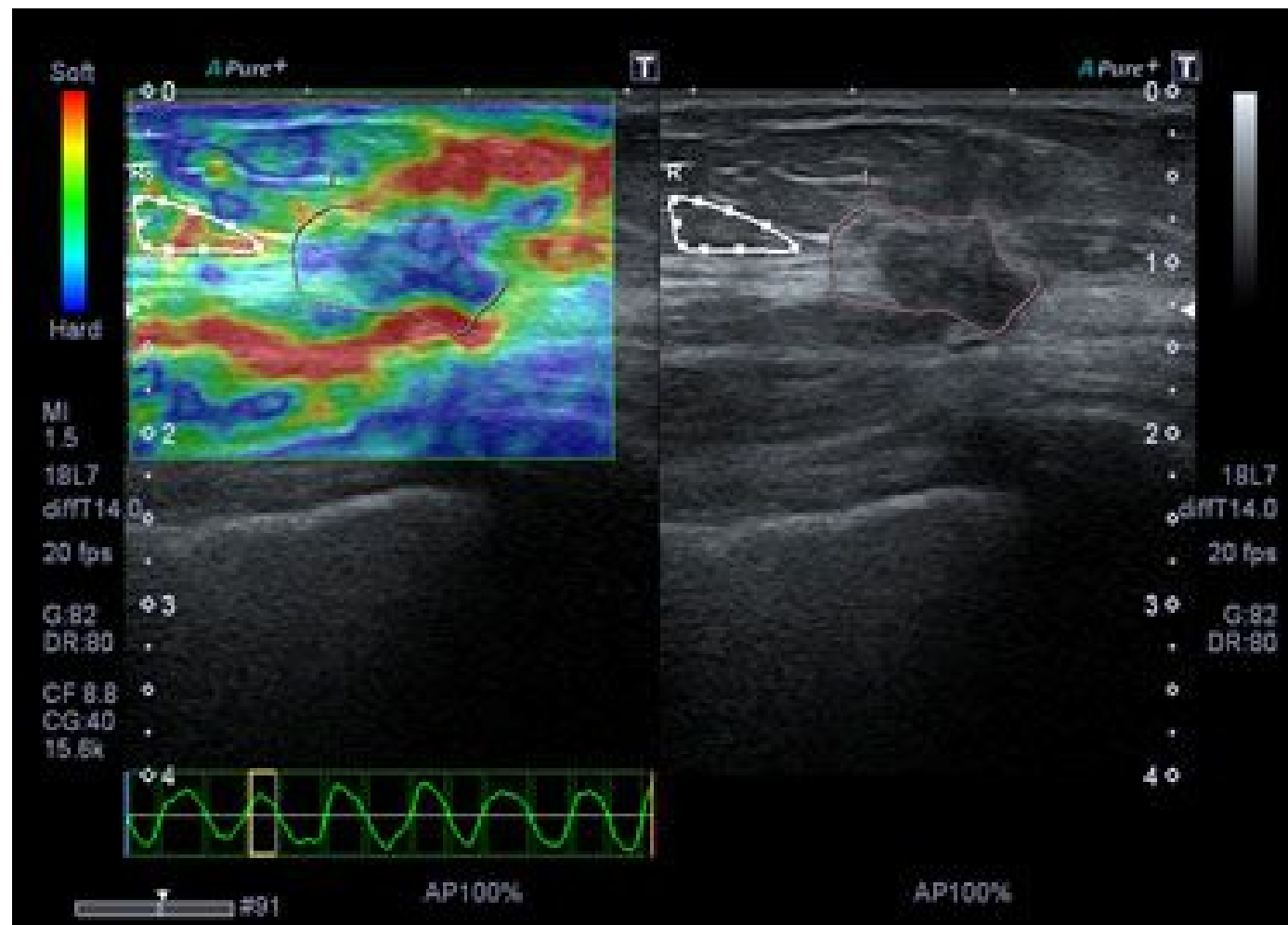


Fig.38

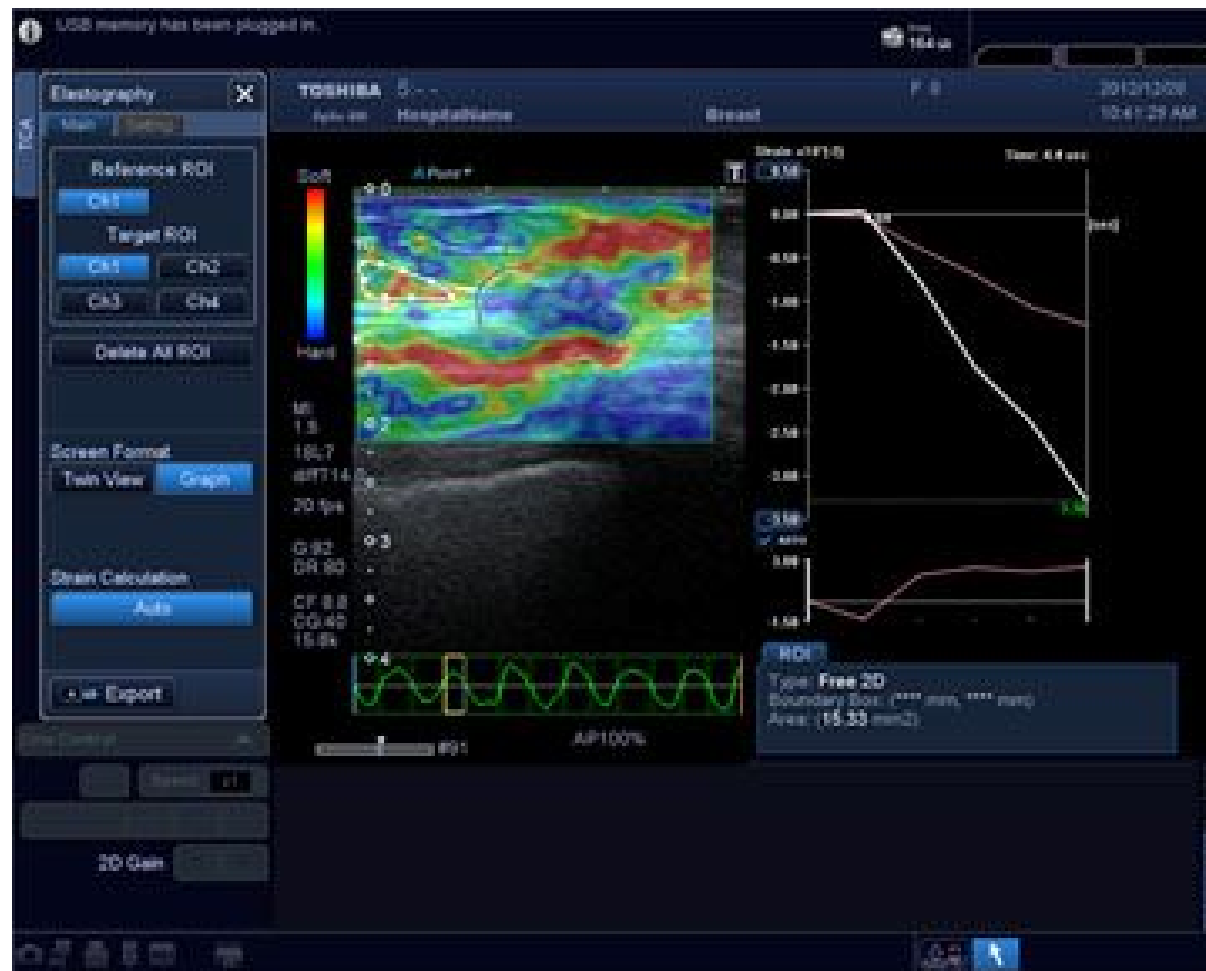


Fig.39

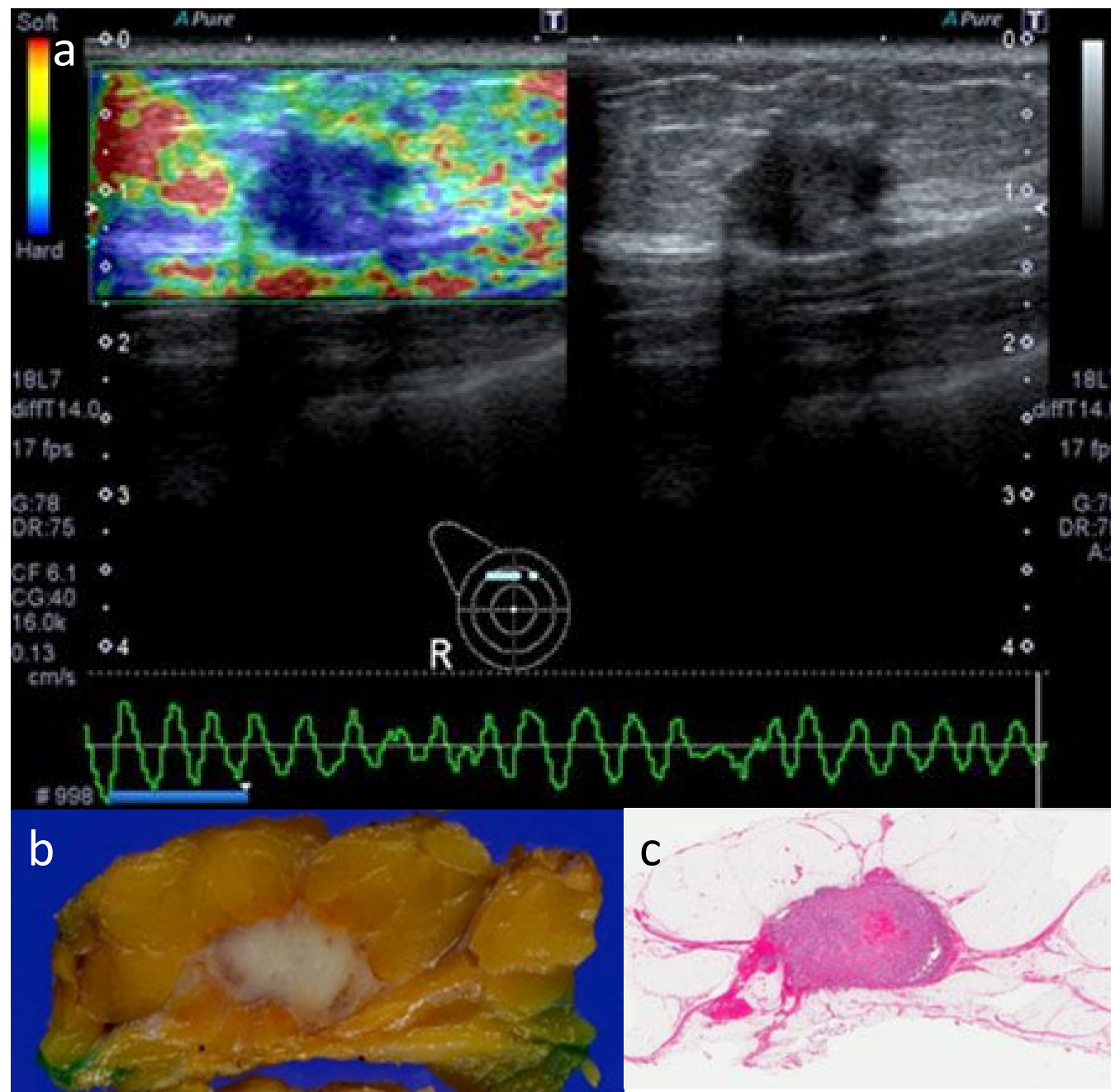


Fig.40

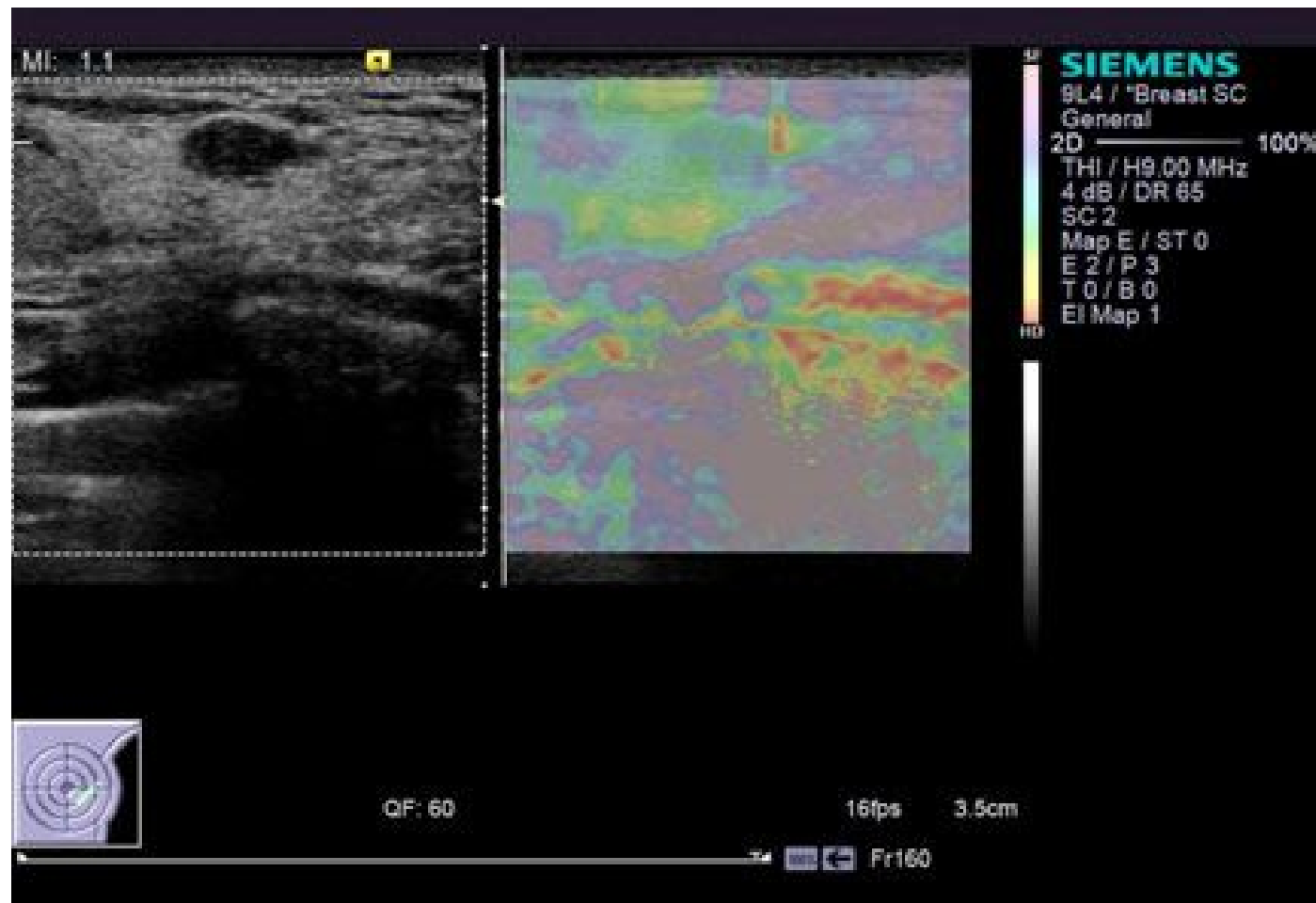


Fig.41

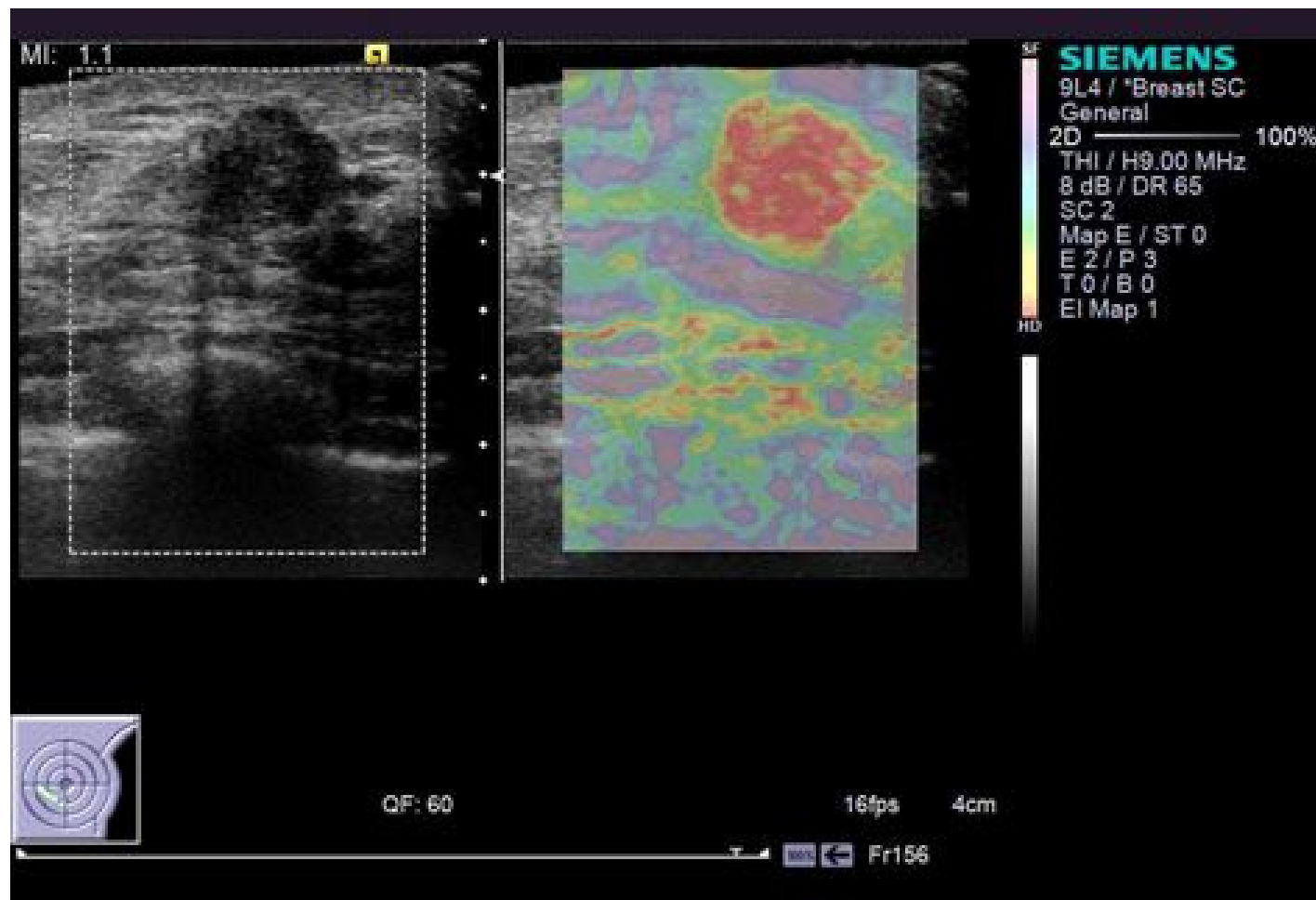


Fig.42

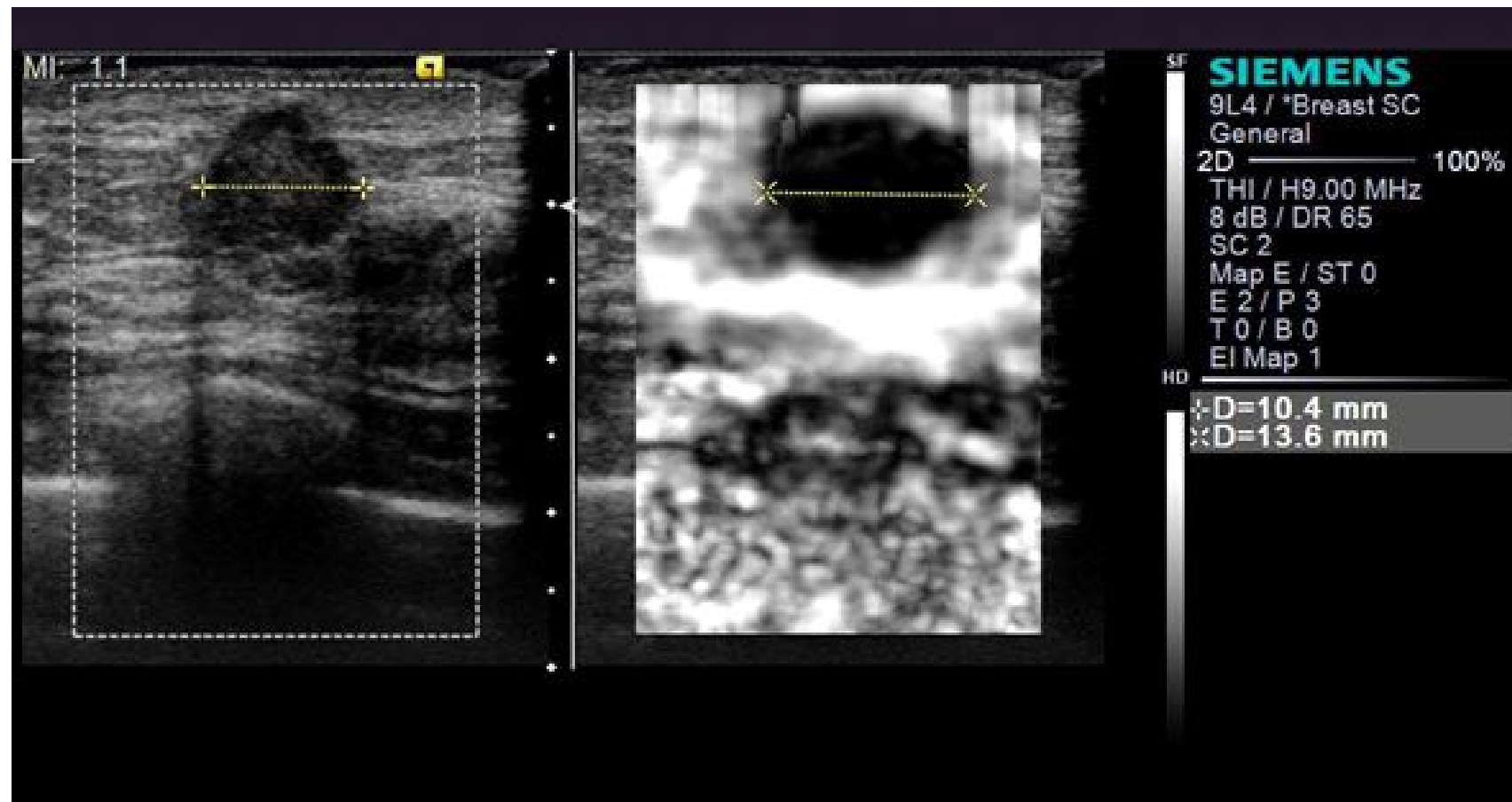


Fig.43

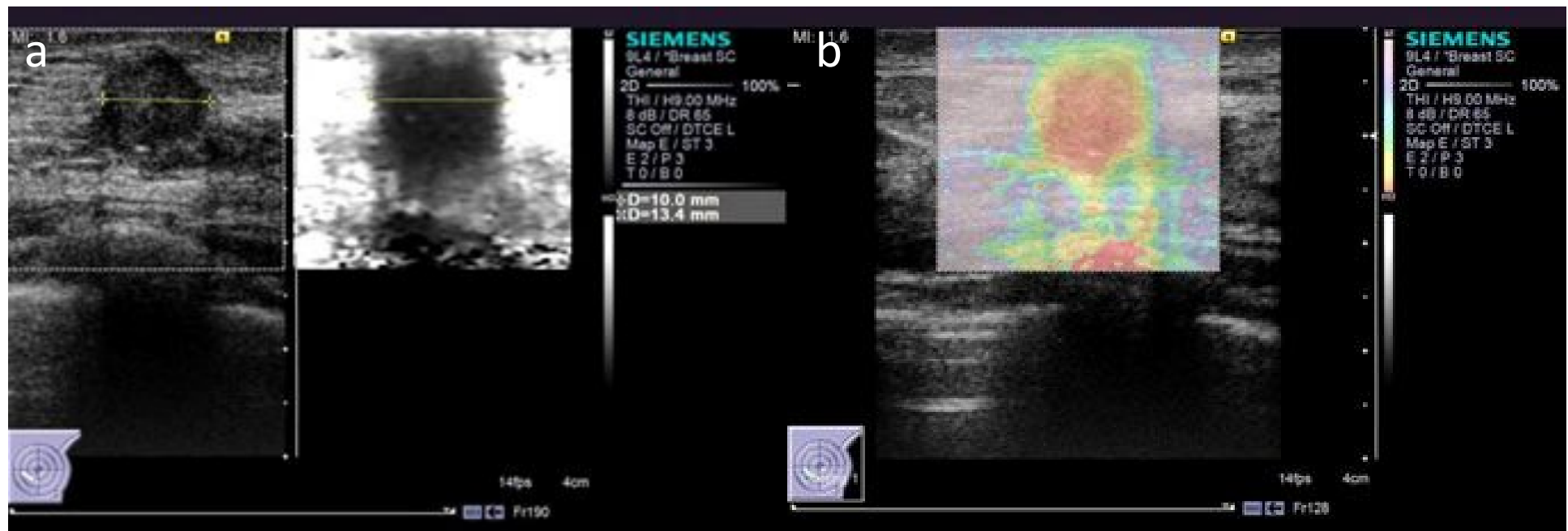


Fig.44

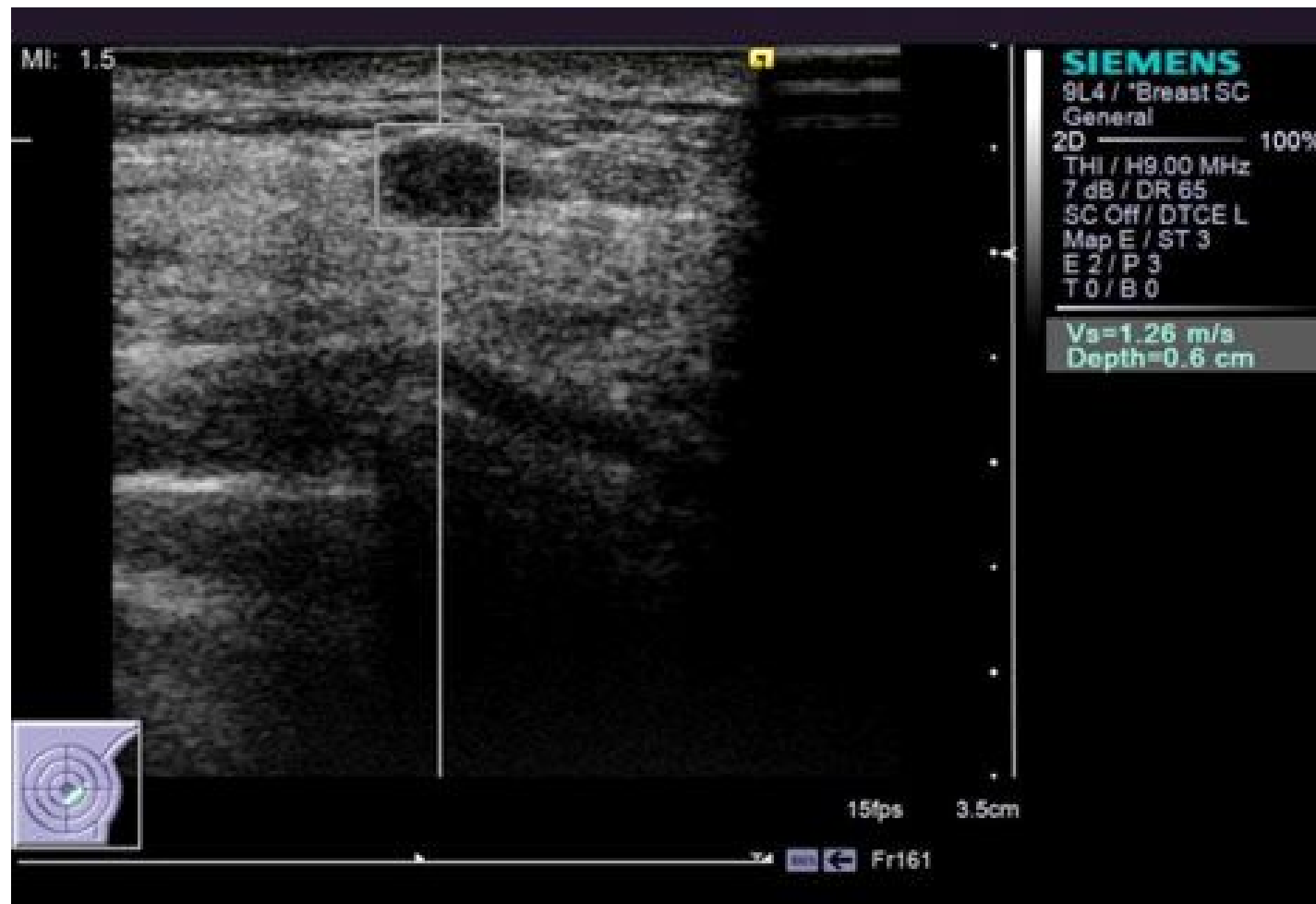


Fig.45

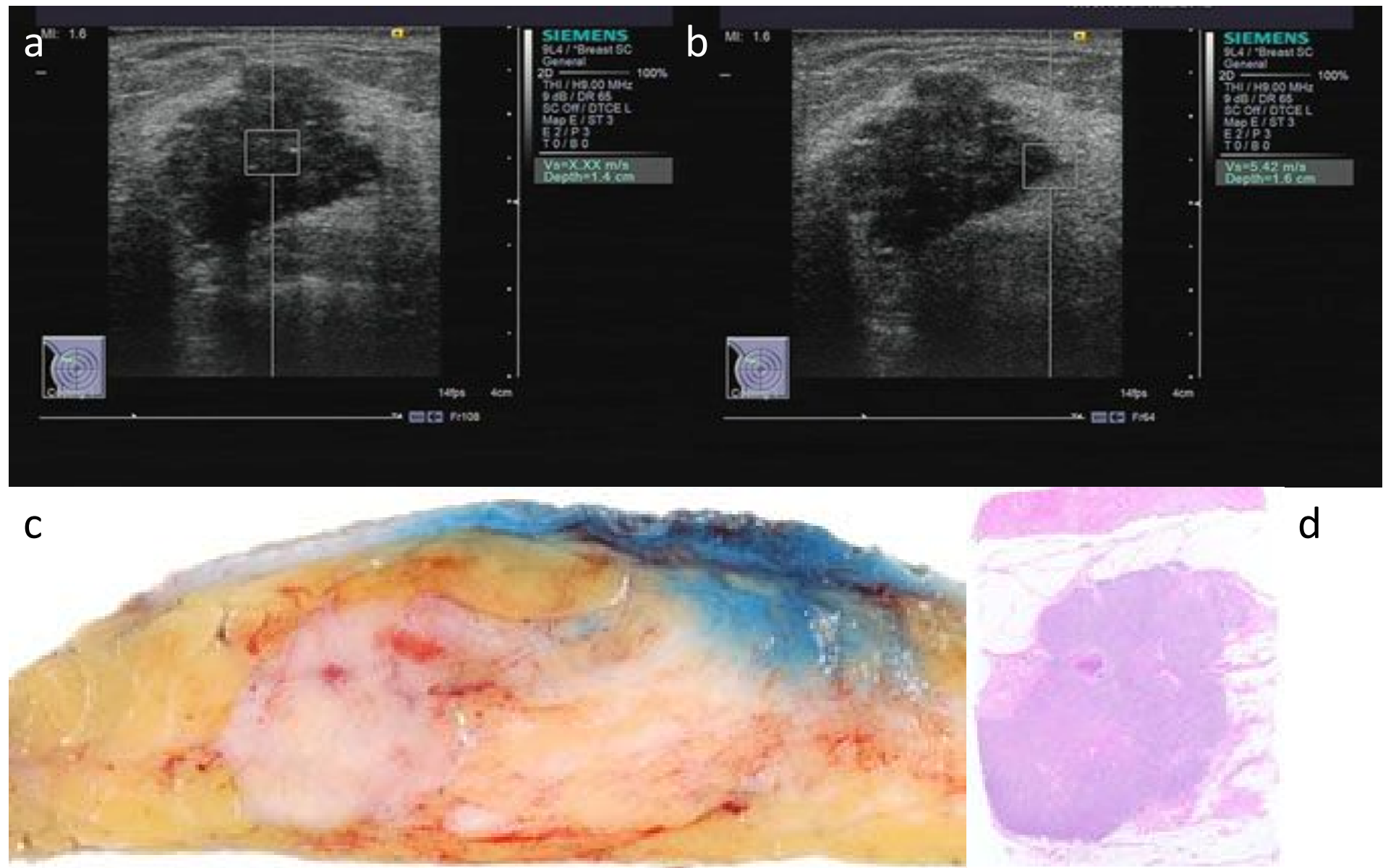


Fig.46

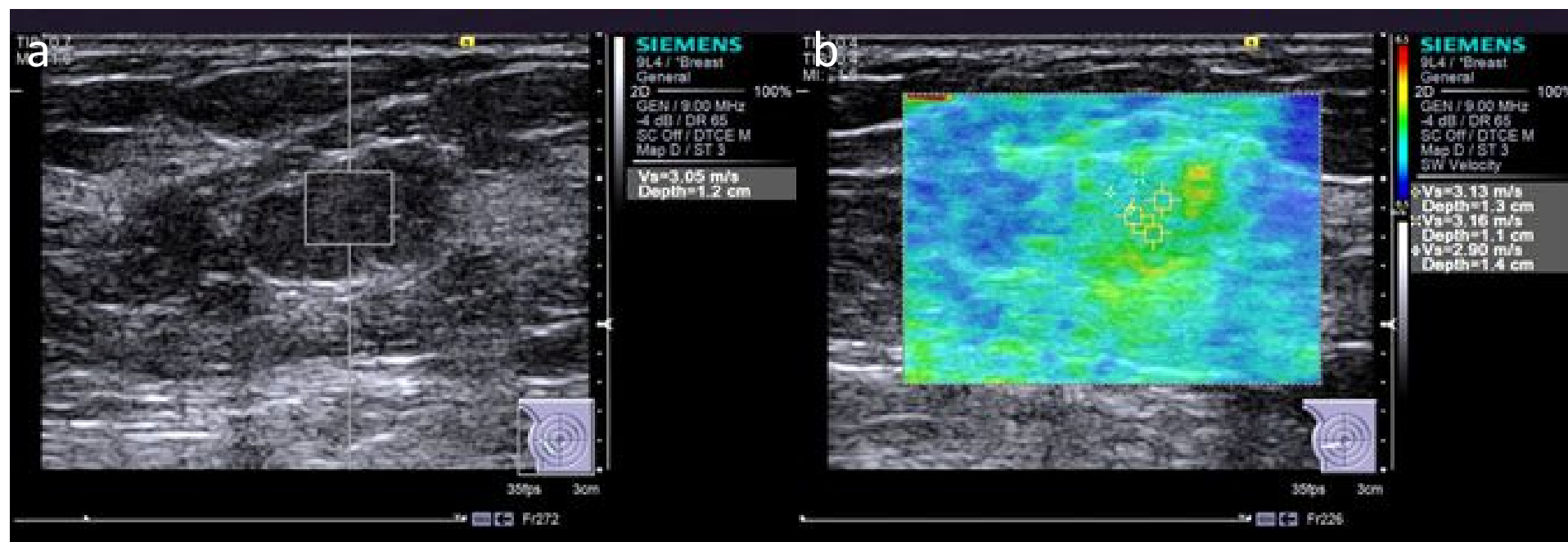


Fig.47

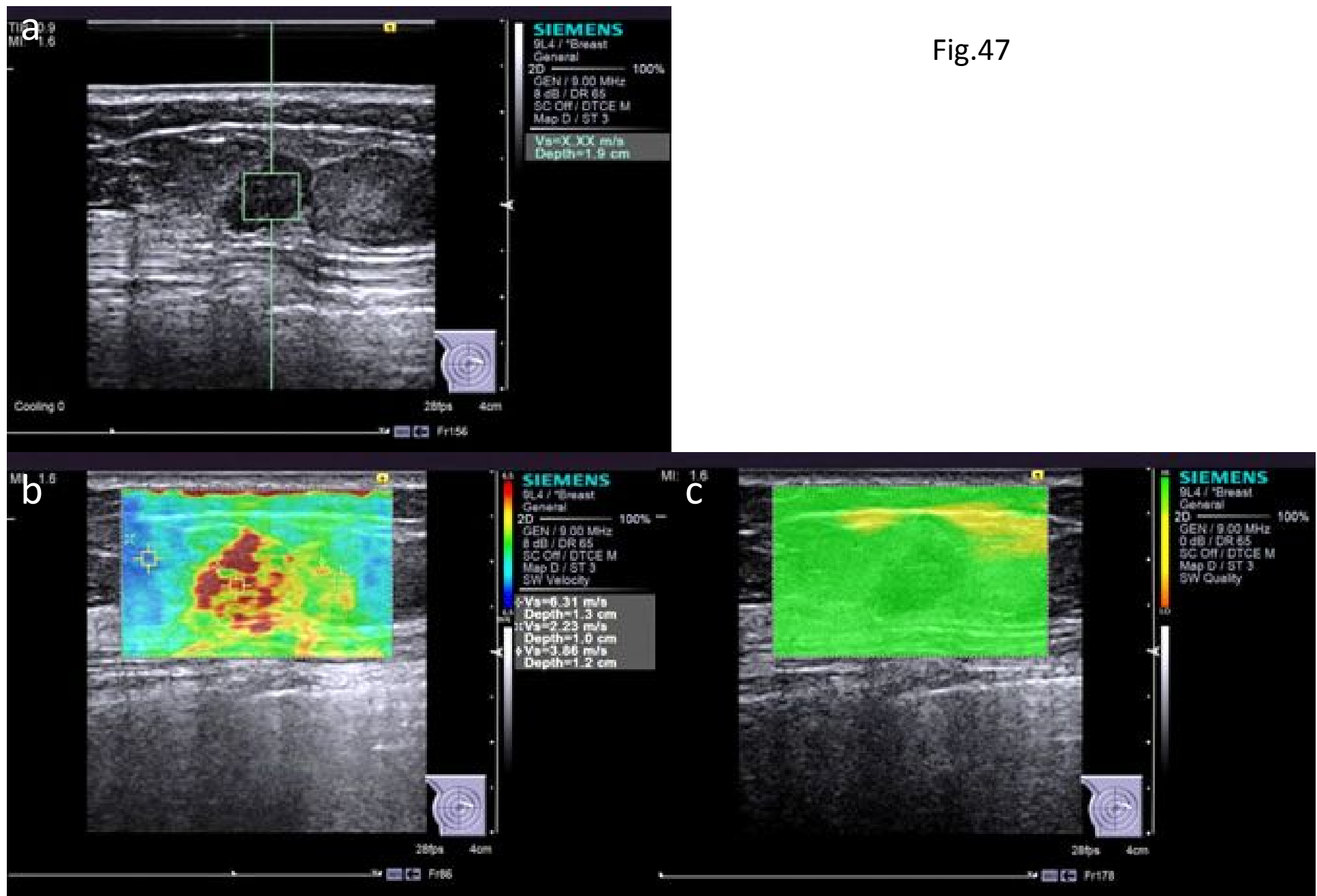


Fig.48

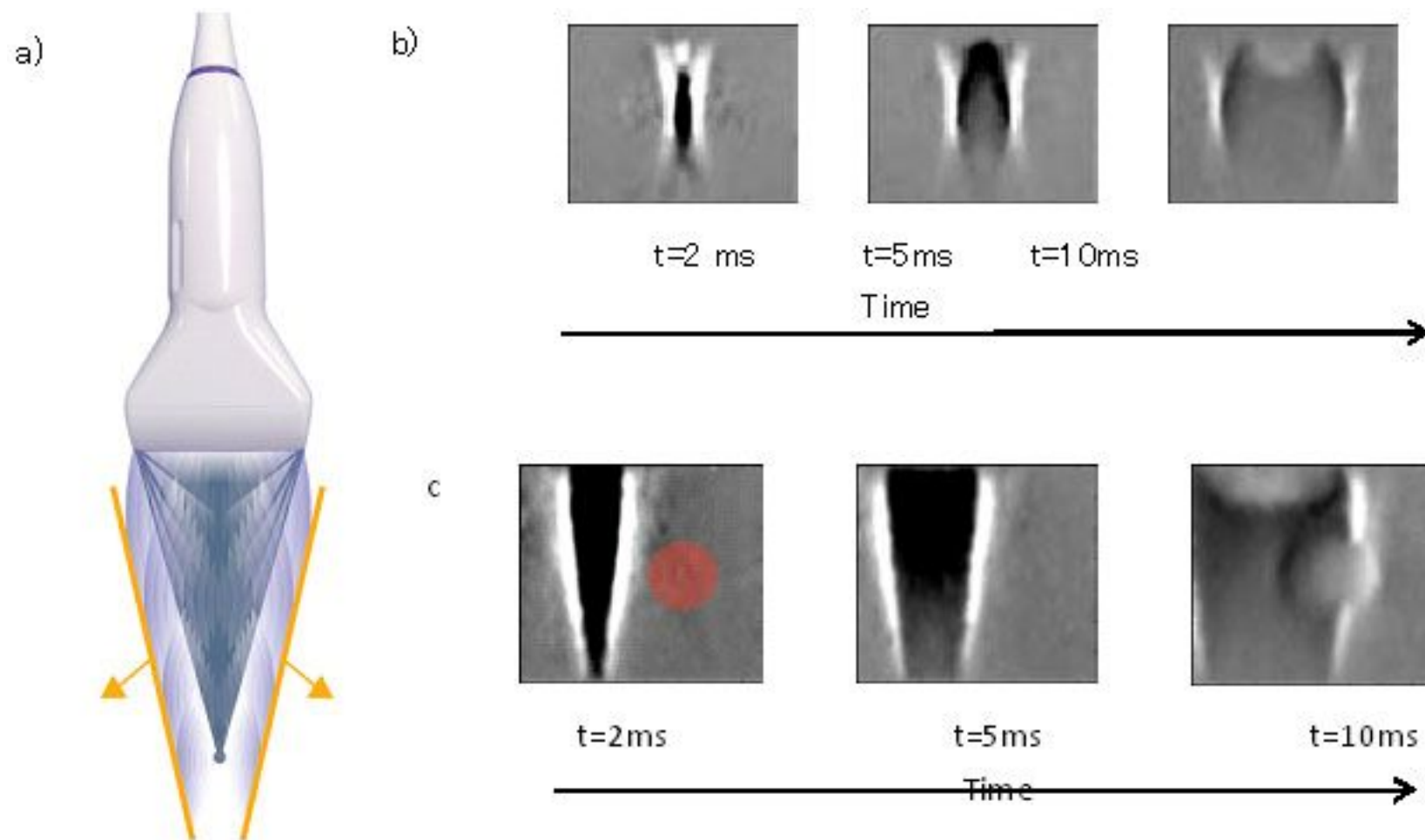
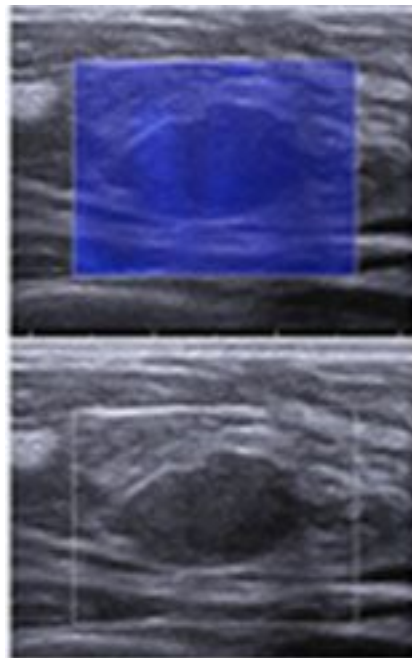
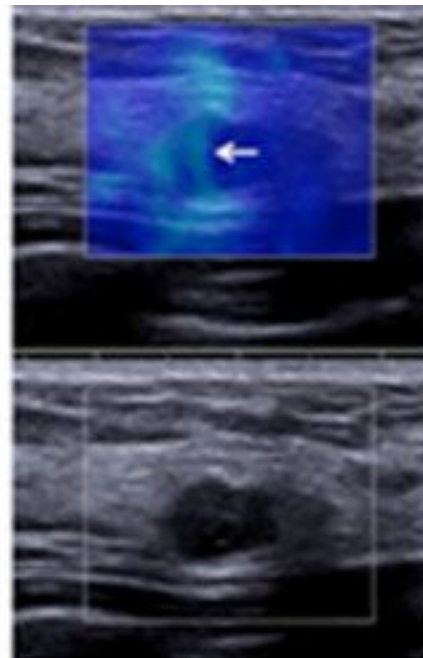


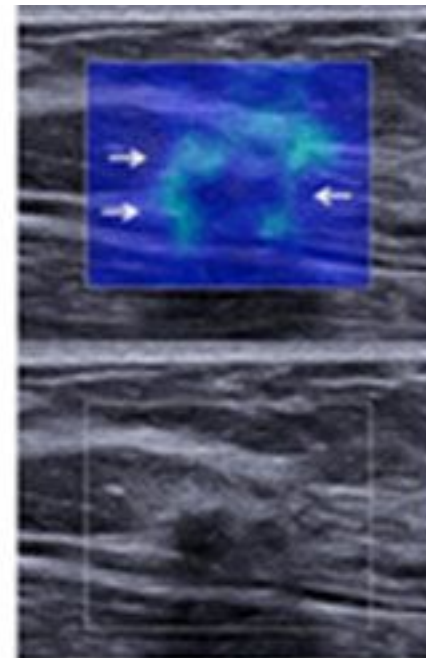
Fig.49



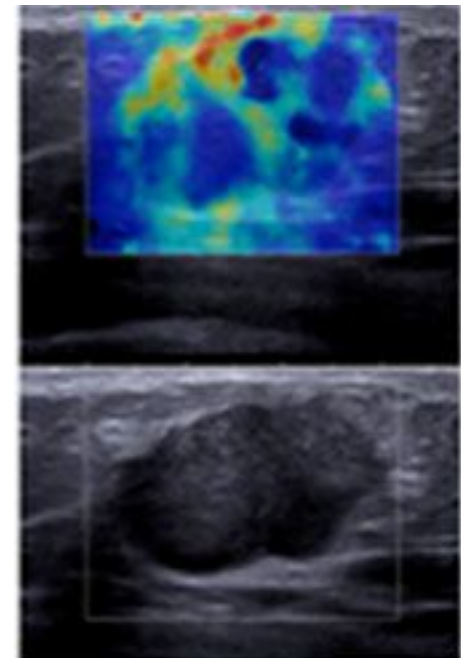
Panoram 1
The lesion is coded blue
homogeneously, no findings



Panoram 2
Vertical strain panoram artifact



Panoram 3
A localized colored area at
the margin of the lesion



Panoram 4
Heterogeneously colored area
in the interior of the lesion

Fig.50

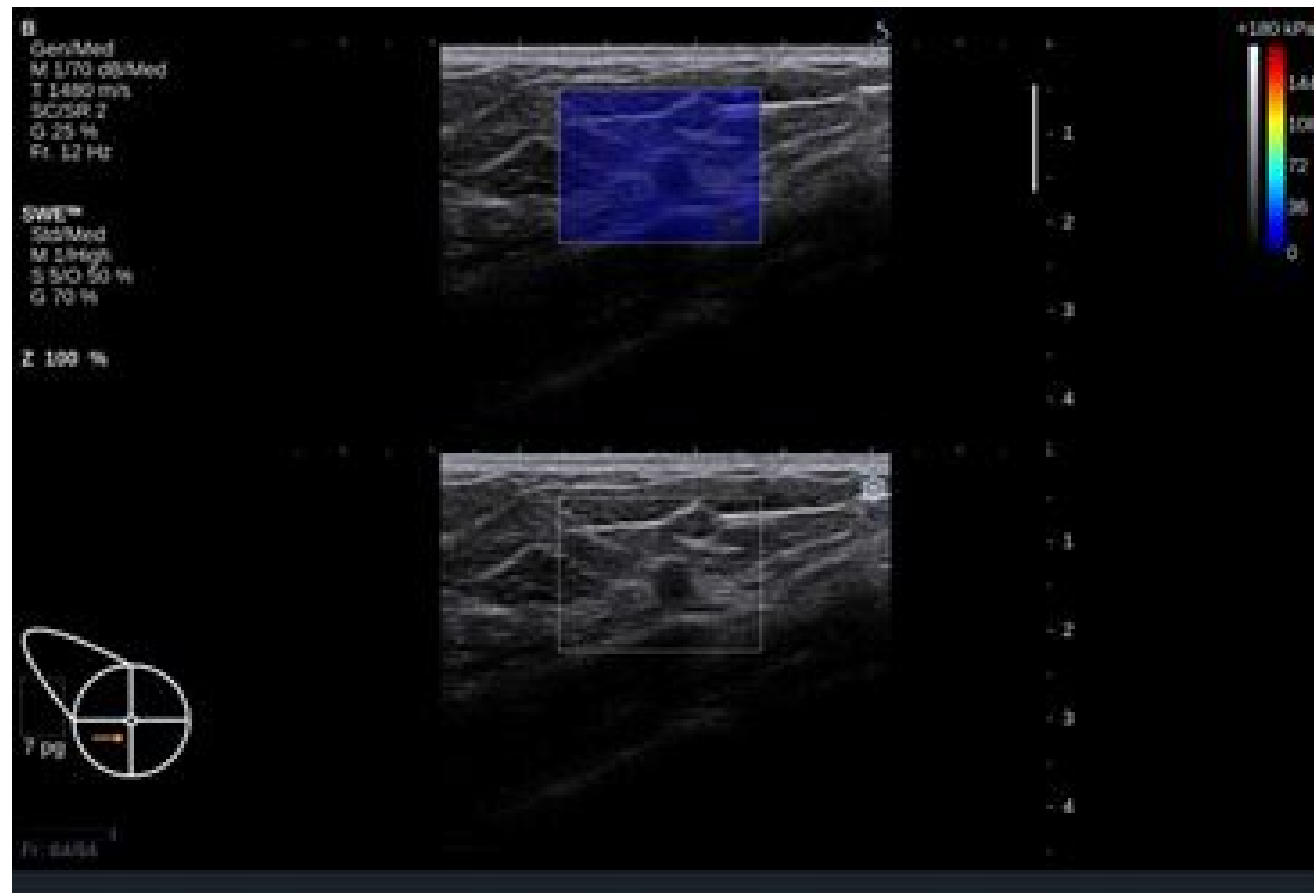


Fig.51

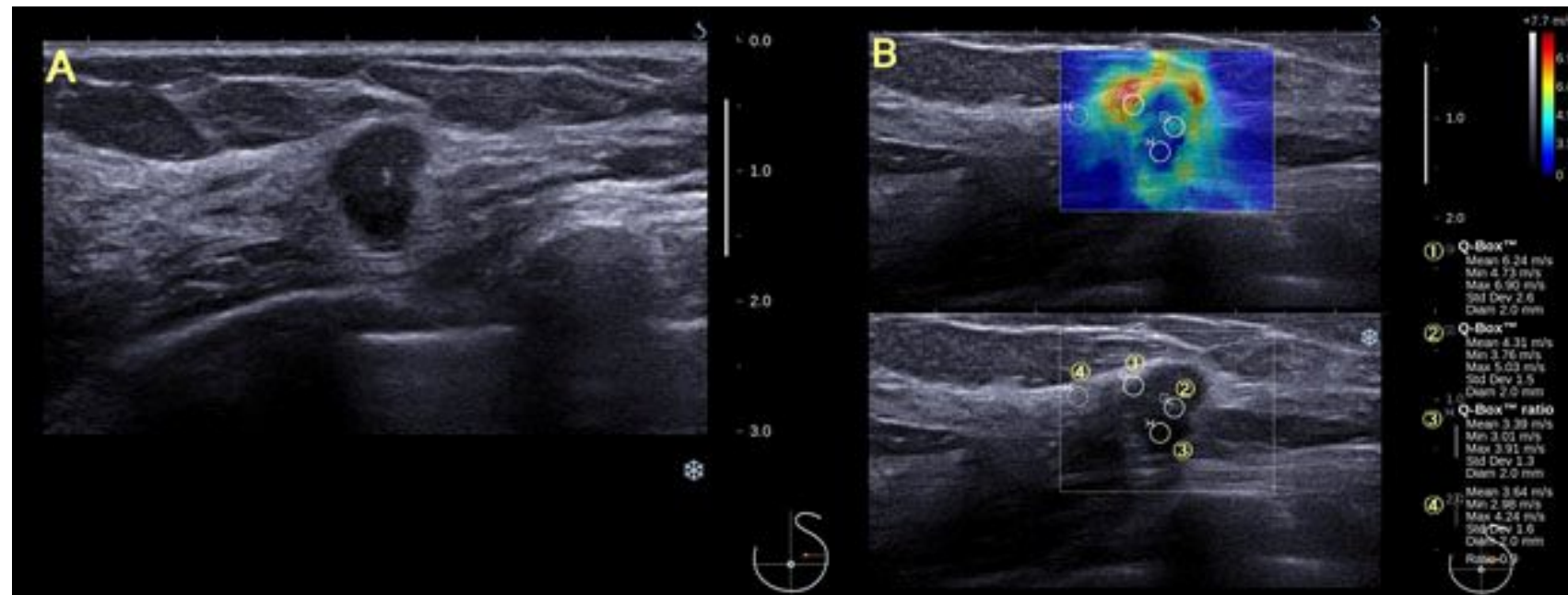


Fig.52

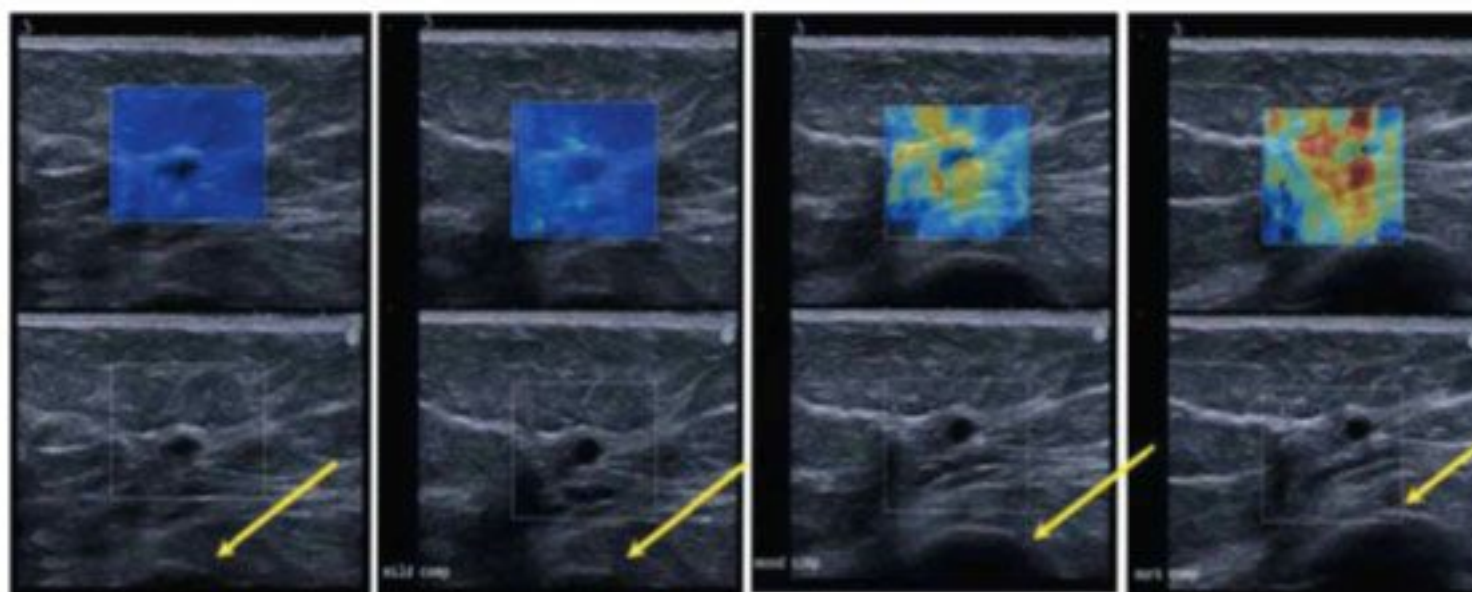
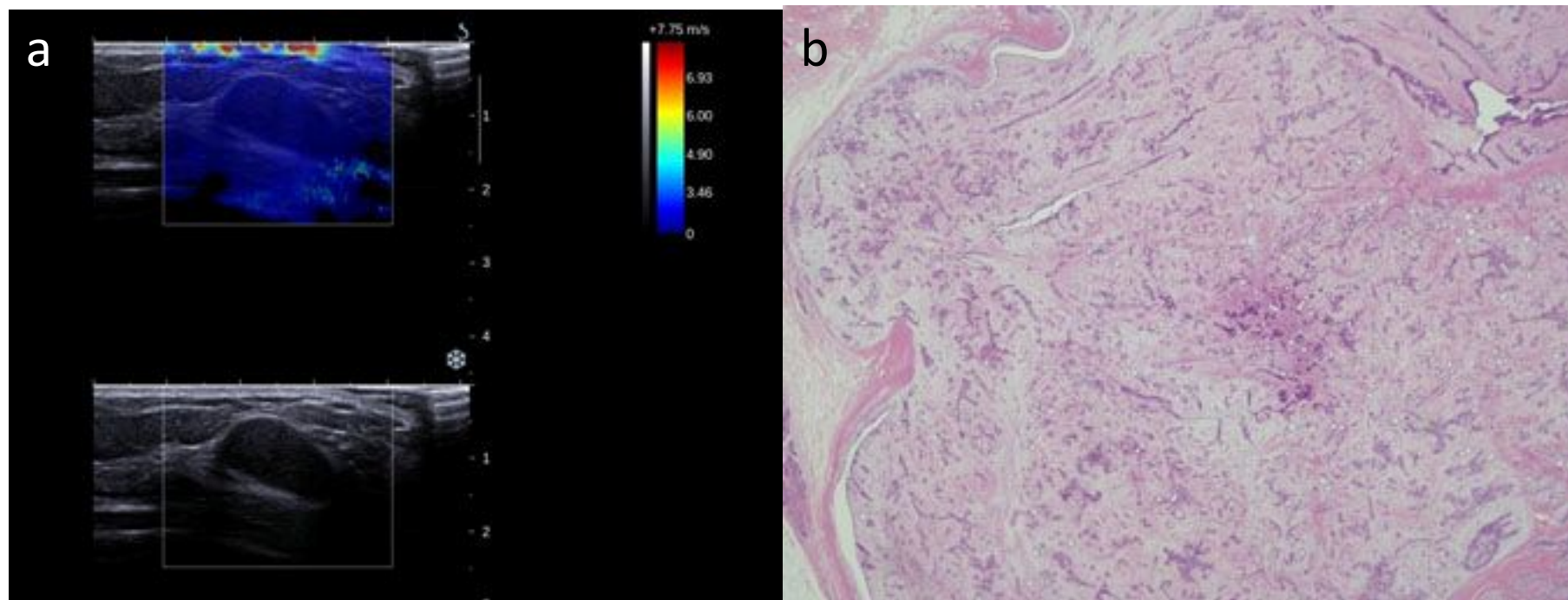


Fig.53



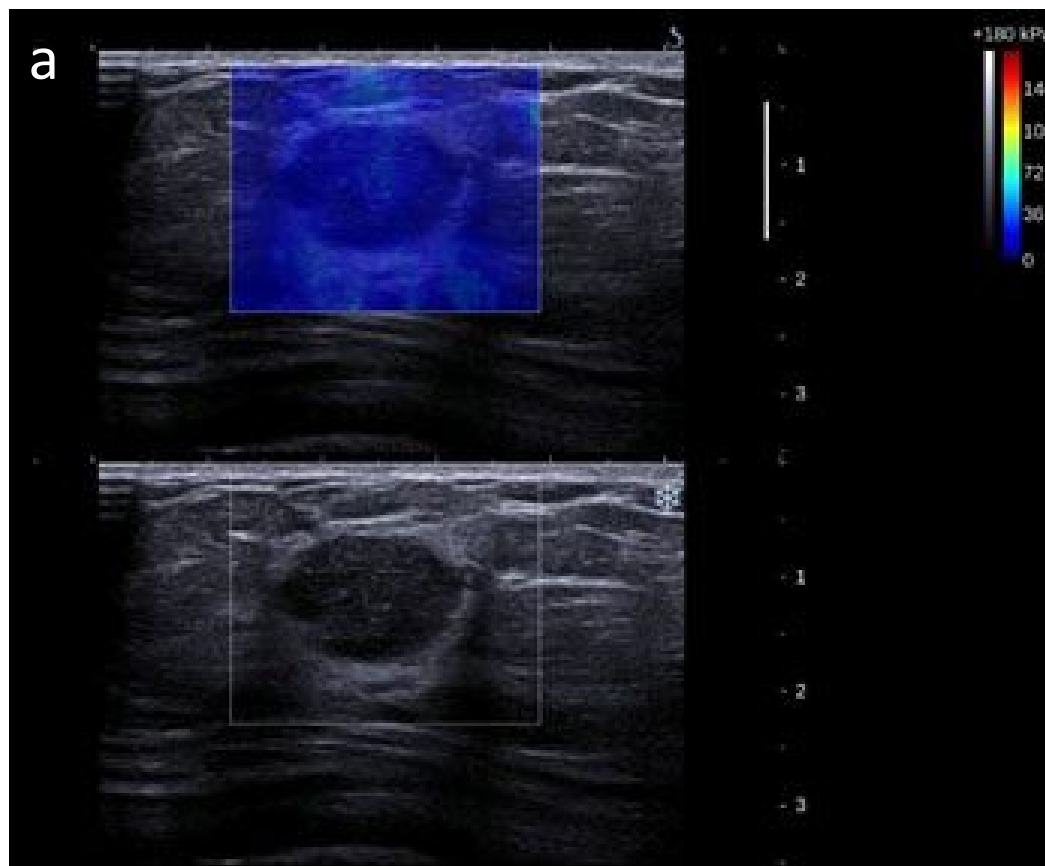
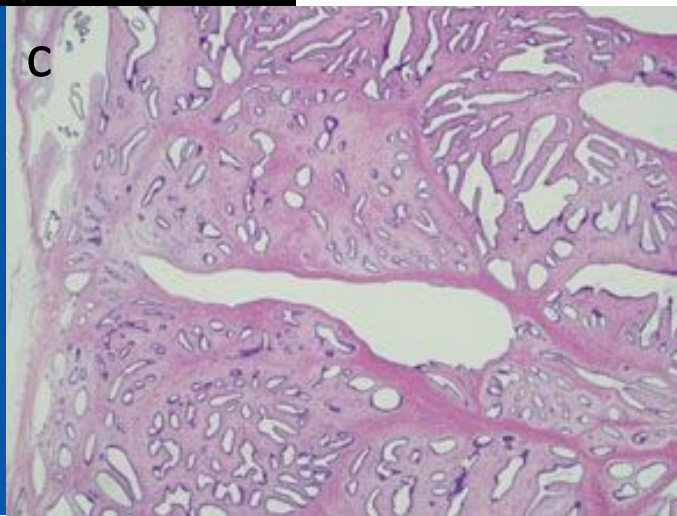
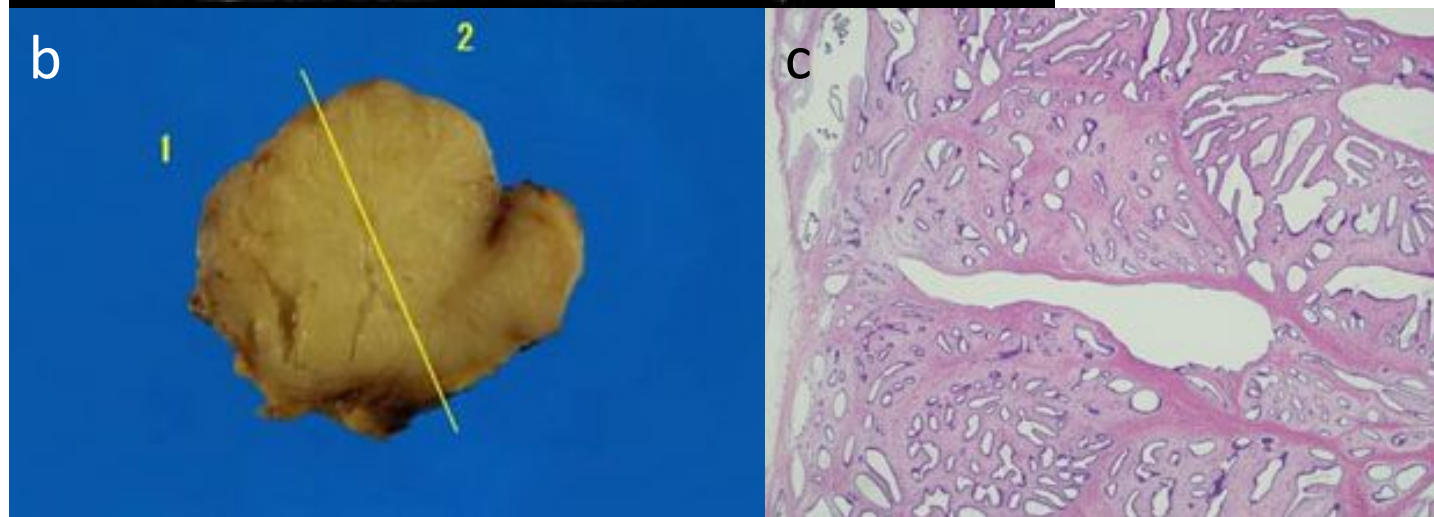


Fig.54



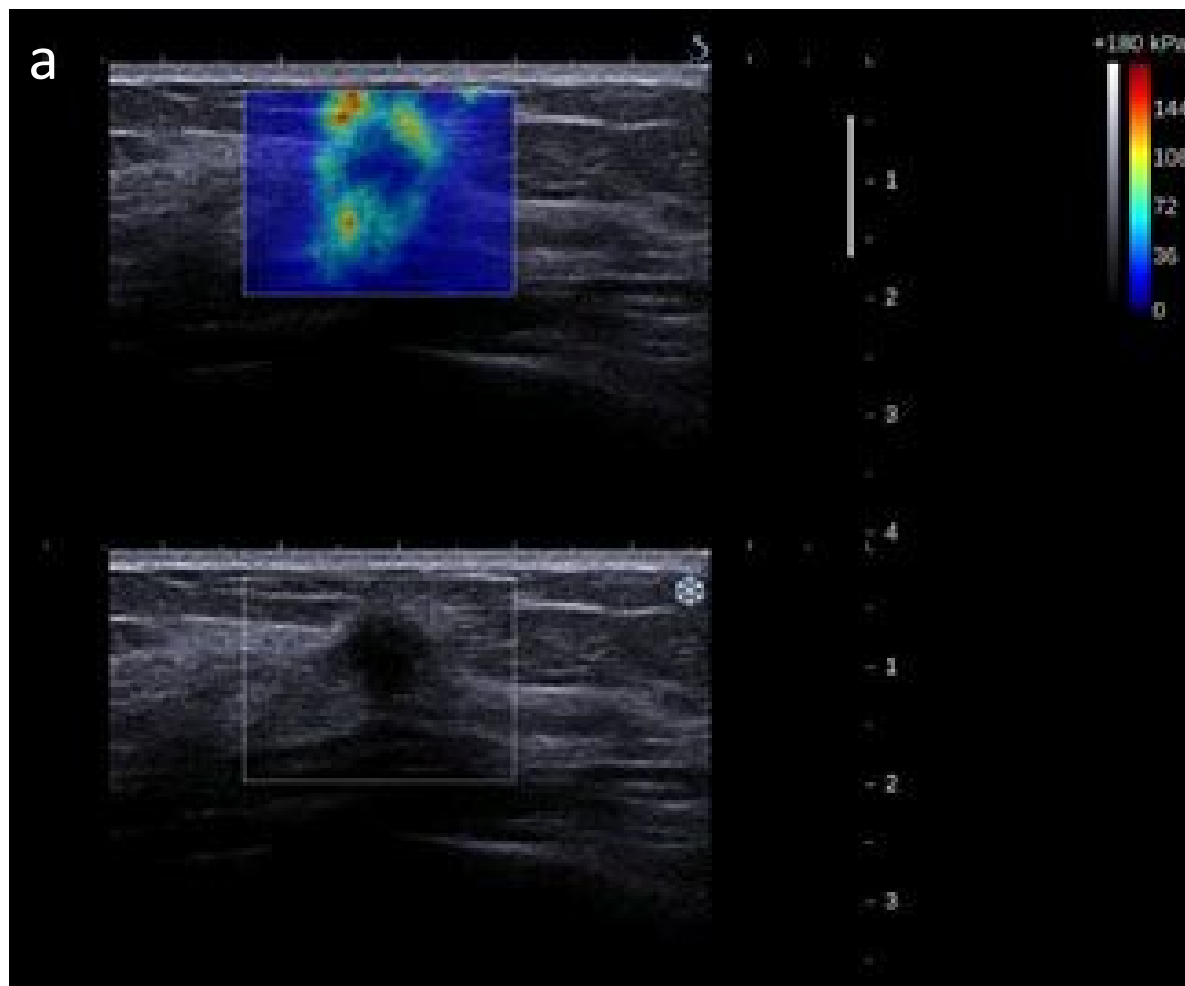


Fig.55

