

新生児・乳児の股関節脱臼診断基準

日本超音波医学会の定めた乳児股関節前額面像(基準断層像)(図1)において、3本の補助線から得られる α 角と β 角を測定する。この計測値及び月齢より、表1に従って分類する。(Grafの許可を得て一部を改変)

日本超音波医学会

用語・診断基準委員会

委員長 田中幸子

乳児股関節脱臼診断基準検討小委員会

委員長 瀬本喜啓

オブザーバー 扇谷浩文 松崎浩巳

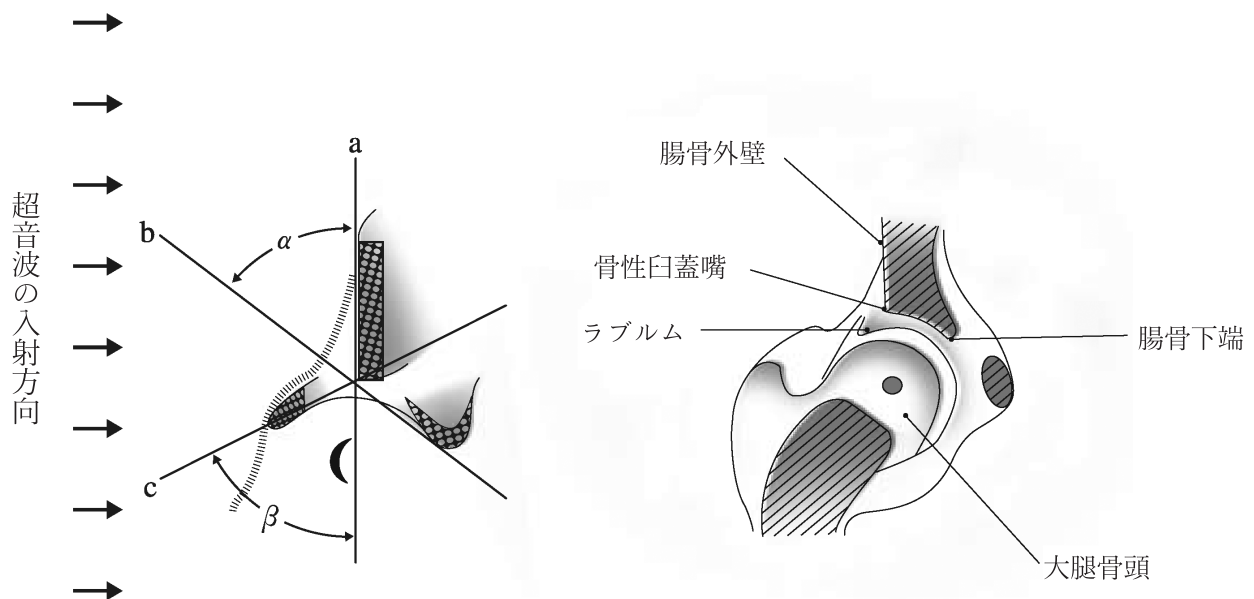


図1:乳児股関節前額面像

a. 基線 (base line)

軟骨膜と腸骨外壁とが接する点を通り、腸骨外壁と平行な線。

b. 骨性臼蓋線 (bony roof line)

骨性臼蓋嘴と腸骨下端を結ぶ線。

c. 軟骨性臼蓋線 (cartilage roof line)

骨性臼蓋嘴とラブルムの中心を結ぶ線

表1 新生児・乳児股関節脱臼の超音波診断分類 (Graf 法改変)

Type		骨性臼蓋嘴の形状	臼蓋軟骨の形状	α 角	β 角 *2
I	正常股関節	角ばっている または やや丸みをおびる	幅が狭い よく骨頭をおおう	$\alpha \geq 60$	
II	II a : 骨性臼蓋の骨化の遅延 (生後 3 か月未満)	丸みをおびる	幅を増す 骨頭をおおう	$50 \leq \alpha < 60$	
	II b : 骨性臼蓋の骨化の遅延 (生後 3 か月以降)		幅が広い		
	II c : 脱臼危険状態	ほぼ骨頭をおおう		$70 \leq \beta \leq 77$	
D	骨頭が求心性を失った状態 (臼蓋の形成不全は type III・IVに比べて軽度)	やや平坦化	骨頭をおおわない	$43 \leq \alpha < 50$	$\beta > 77$
III	III a : 脱臼 臼蓋軟骨部にエコーが出現 しない	平坦化	臼蓋軟骨は骨頭の内 上方に存在する	$\alpha < 43$ *1	
	III b : 脱臼 臼蓋軟骨部にエコーが出現 する				
IV	完全脱臼				

*1 臼蓋軟骨が明らかに内側にある場合は、 α 角を計測する必要はない。

*2 β 角は Type IIc と Type D の判別時のみに用いる。

注 (Type D は脱臼危険股の意味で、Type II d ではない。)

参考文献

- 1) Graf R. Guide to sonography of the infant hip. Stuttgart, Thieme Medical, 1987. p. 42-53.
- 2) 瀬本喜啓, 小野村敏信. 乳幼児股関節に対する超音波断層診断法. 別冊整形外科・新しい画像診断(林浩一郎編集) 1998; 327-32.
- 3) 本間政文, 畠山征也. 乳児先天股脱における超音波診断法と X 線診断法と比較. 日整超研誌 1992; 4: 64-7.
- 4) 山崎 謙, 黒木良克, 斉藤 進, ほか. 先天股脱の股関節造影像と超音波増の比較. 日整超研誌 1993; 5: 75-8.

Criteria for the diagnosis of developmental dysplasia of the hip joint

Terminology and Diagnostic Criteria Committee of The Japan Society of Ultrasonics in Medicine

Chairperson: Sachiko Tanaka

Subcommittee of Diagnostic Criteria for developmental dysplasia of the hip joint of The Japan Society of Ultrasonics in Medicine

Chairperson: Yoshihiro Semoto

Observers: Hirofumi Ohgiya, Hiromi Matsuzaki

A frontal image of the hip joint of an infant, defined as standard ultrasonographic image by the Japan Society of Ultrasonics in Medicine (Fig.1), is used for the classification. The angles α and β formed by the three reference lines shown in Fig.1 are measured.

Developmental dysplasia is classified on the basis of these two angles and the age of the infant, as shown in Table 1 (reproduced with modification with permission of Graf).

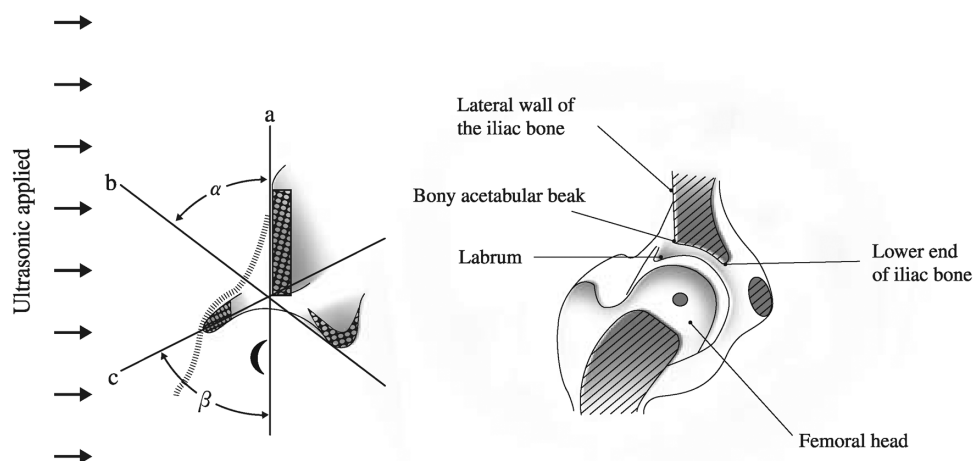


Fig.1. Frontal image of the hip joint. **a** Baseline: a line passing the point of contact between the perichondrium and the lateral wall of the iliac bone that is parallel to the lateral wall of the iliac bone. **b** Bony roof line: a line connecting the bony acetabular beak and the lower end of the iliac bone. **c** Cartilage roof line: a line connecting the bony acetabular beak and the center of the labrum

Table 1. Classification of developmental dysplasia of the hip joint

Type	Shape of bony acetabular rim	Shape of acetabular cartilage	α angle	β angle ^b	
I	Normal hip	Angular or slightly roundish	Narrow; the femoral head is covered well	$\alpha \geq 60$	/
II	II a. Delayed ossification of bony acetabulum (less than 3 months after birth) II b. Dysplasia of bony acetabulum (after 3months)	Roundish	Wider; the femoral head is covered	$50 \leq \alpha < 60$	
	II c. Danger of dislocation		Wider; the femoral head is covered almost completely		$70 \leq \beta \leq 77$
D	Afferent nature lost in the femoral head (acetabular dysplasia is less severe than types III and IV)	Slightly flat	Femoral head is not covered	$43 \leq \alpha < 50$	$\beta > 77$
III	III a. No echo in acetabular cartilage III b. Echo seen in acetabular cartilage	Flattened	Acetabular cartilage located superomedial to the femoral head	$\alpha < 43^a$	/
IV	Severe dislocation		Acetabular cartilage located inferomedial to the femoral head		

^aThe angle α does not need to be measured if the acetabular cartilage is evidently located medially

^bThe angle β is used only for discrimination of Type II c from Type D

References

1. Graf R. Guide to sonography of the infant hip. Stuttgart: Thieme Medical 1987. p.42-53.
2. Semoto Y, Onomura T. Ultrasonography of the infant hip. Orthopedic Surgery 1988;13:327-32 (in Japanese).
3. Honma M, Hatakeyama S. The comparison between sonography and roentgenography in CDH screening. J JaSOU 1992;4:64-7 (in Japanese).
4. Yamazaki Y, Kuroki Y, Saito S, et al. A comparison between the arthrogram and the sonogram in congenital dislocation of the hip. J JaSOU 1993;5:75-8 (in Japanese).