

## SPECIAL ARTICLE

The Terminology and Diagnostic Criteria Committee of The Japan Society of Ultrasonics in Medicine

## Examination guide for ultrasonic image presentation and measurement of the ophthalmic region

### Introduction

In current commercial ophthalmic ultrasound diagnostic systems, image display methods and sizes of probes vary. In clinical practice, B-mode scanning is performed to detect both static and dynamic information. The former is primarily used to obtain the positional relationship between lesions and structures in the eye and the orbit, and the latter to detect motion in the eye, for example, motion of the vitreous body, iris, or detached retina. It is useful to devise an imaging diagram to help in understanding the relations of lesions, because there are few anatomical landmarks for any cross-sectional image inside or outside the eyeball.

In ophthalmology, ocular axial length measurement can be made in two ways: the first is from the cornea to the back of the sclera for an index of the growth process, and the second is from the cornea to the retina for intraocular lens implant operations. Therefore, it is important to obtain reliable values for specific measurements in the commonly utilized A-mode.

### Presentation guide for the identification of sections (B-mode)

To map out the anatomy in any scanning plane, the graphical interpretation should include indicators of left and right, upper and lower, and nasal and temporal directions, using the optic nerve and extraocular muscles as base points.

Moreover, the direction of transducer motion should be indicated.

A horizontal section image should display an eyeball seen from beneath (i.e. from the caudal side of the body), as for computed tomography and magnetic resonance imaging.

Figure 1 shows a right eye on a plane that includes the extraocular muscles in cross section. Figure 2 shows a horizontal section.

### Examination guide for measuring the length of the eyeball

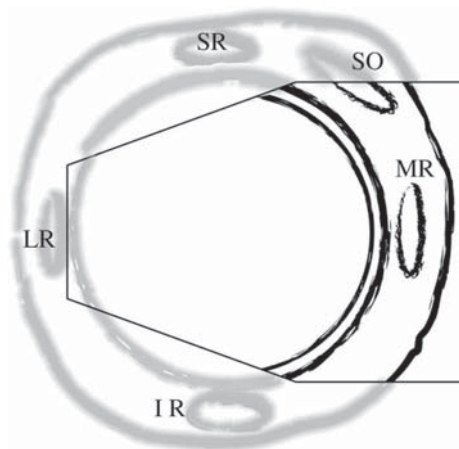
- 1) The system should allow input of the following values: acoustic velocities of the cornea, aqueous fluid, crystalline lens, vitreous body, and foreign material such as an intraocular lens or silicon.
- 2) The system should operate with the patient in the dorsal or sitting position, using either the contact method or immersion testing.
- 3) Examinations should be performed with precautions taken to prevent infections and corneal injury. Usage of ophthalmologic coupling media is recommended when necessary.
- 4) When using the contact method, care should be taken not to deform the cornea by exerting too much pressure.
- 5) In normal eyes, adjust the gain so as to produce reflections that are close to saturation and produce clear echoes from the corneal surface, anterior and posterior

Chairperson: Sachiko TANAKA

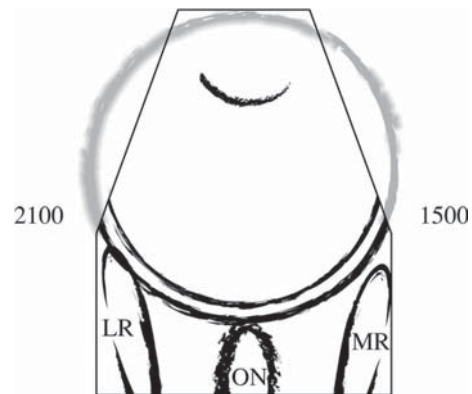
Members of The Ophthalmology Subcommittee of The Terminology and Diagnostic Criteria Committee of The Japan Society of Ultrasonics in Medicine

Chairperson: Yasuo SUGATA

Members: Sadanao TANE, Atsushi SAWADA,  
Tomihiko HIROKAWA, Sayuri FUJIOKA  
Observers: Sachiko HONMURA, Yuzo NAKAO,  
Hideyuki HAYASHI



**Fig. 1.** A right eye when the scanning probe is pointed toward the nasal side from the corneal limbs. *SR*, superior rectus muscle; *SO*, superior oblique muscle; *MR*, medial rectus muscle; *IR*, inferior rectus muscle; *LR*, lateral rectus muscle



**Fig. 2.** A horizontal section of the right eye when the scanning probe is pointed toward the posterior pole from the top of the cornea, drawn from the caudal side of the body (from beneath the eyeball). *MR*, medial rectus muscle; *LR*, lateral rectus muscle; *ON*, optic nerve; 1500, three o'clock side of the eyeball; 2100, nine o'clock side

surfaces of the lens, and the anterior surface of the retina.

- 6) In eyes with cataract, evaluate the measurement values considering the acoustic velocity in a lens with cataract.
- 7) In eyeballs with severe myopia and in eyeballs that have suffered from previous surgery, evaluate the values considering the specific tilt of the posterior pole of the eyeball.